

I N A U G U R A L I S S U E

TOS TODAY

VOL 1 | ISSUE I | 2015



In this Issue...

- OCT assessment of PDEK graft
- ReLEx SMILE - The Future of Refractive Surgery
- Keratoconus - A practical approach in diagnosis & management
- PFV with unusual finding of lenticular cyst
- Chronic Progressive External Ophthalmoplegia
- Clinical Profile of Ocular Surface Squamous Neoplasia
- Intraocular Cysticercosis
- Perfluorocarbon Liquid as short-term tamponade for posterior giant retinal tear
- Plateau Iris
- Retinal OCT
- Lid & Facial Rejuvenation

www.tsos.co.in

Give dry eyes the **OSMO** edge

OSMODROPS

CMC 0.5% + Glycerine 0.9%

EDGE OVER HYDRATION

Osmoprotection

Protects ocular surface due to tear film hyperosmolarity¹

Symptomatic relief

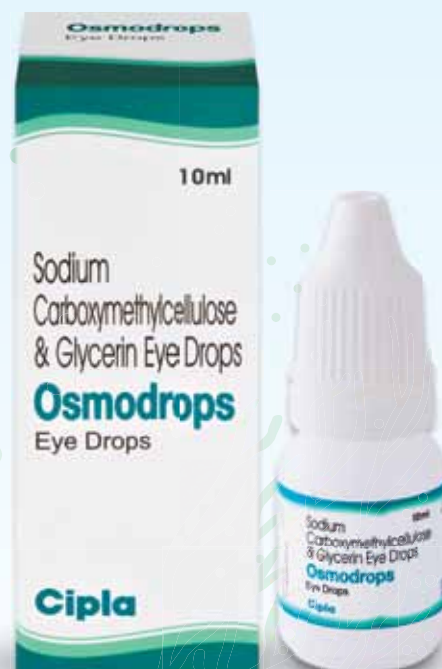Greater symptomatic relief compared to other tear substitutes²

Moisturization

CMC & Glycerine provides a hydrating protective shield on the ocular surface²

Ocular surface health

Significantly increases the thickness and morphology of cornea³



Ref:

1. Molecule Vision 2010;16:1823-1831

2. Clinical Ophthalmology. 2009;3:33-39

3. Poster no.: 126-A153. Presented at: 80th Annual Meeting of the Association for Research in Vision and Ophthalmology (ARVO); April 27-May 1, 2008; Fort Lauderdale, FL

Editorial Board



Mallika Goyal, MD
Senior Vitreoretinal Surgeon
Apollo Hospitals, Hyderabad
drmallikagoyal@gmail.com



Padmaja Kumari Rani, MS FNB
Senior Vitreoretinal Surgeon
LV Prasad Eye Institute, Hyderabad
rpk@lvpei.org



Muralidhar Ramappa, MD
Consultant, Pediatric Cornea & Anterior
Segment services
L V Prasad Eye Institute, Hyderabad
muralidhar@lvpei.org



Syed Maaz Mohiuddin, MS
Centre For Sight & New Vision Lasers, Hyderabad
docmaaz@yahoo.co.in



Giridhar Bellamkonda, MS
Senior Assistant Professor
Regional Eye Hospital
Kakatiya Medical College, Warangal
bgiridharreddy@gmail.com

Editor's Note

*D*ear Members TOS,

This is the inaugural issue of the newly formed Telangana Ophthalmological Society (TOS).

On behalf of the Editorial Board I thank the members of the Society and the TOS Executive Committee for nominating us to this position. We will do our best to provide a vibrant journal that represents current Ophthalmology in the State and Country.

We have a very active and diverse Editorial Board. Special gratitude and acknowledgement is due to Dr Padmaja Rani for her dedication and sincerity; and to Dr Muralidhar Ramappa for his prompt and no-nonsense approach to editing.

Please send in your articles, challenging case reports, or experiences with clinical photographs *online* to us at the email address of any of the Editorial Board member.

All submissions will be evaluated by the Editorial Board, and the merit of the scientific matter will be the only criterion for selection for publication. Every effort will be made to publish all submitted scientifically sound material.

We look forward to receiving contributions from all members of the Society for our future issues,

Sincerely,

Mallika Goyal, MD
Editor Publications
Telangana Ophthalmological Society

Retina-Vitreous Service

Apollo Hospitals
Jubilee Hills, Hyderabad, Telangana - 500096
Phones: 040-2355 4563, 2360 7777 (M) 98492 70994
Fax: 040-23608050
Email: drmallikagoyal1@gmail.com



The state of Telangana and the Telangana Ophthalmological society have after all become a reality. Whether this is for good or not is certainly debatable. However, I am convinced that if we are positive in our thoughts and actions we can make use of this opportunity and take the TOS to great heights. On this occasion I would like to share some of my thoughts.

The first President, Secretary and all the office bearers were elected unanimously. A great Honour indeed. But, with this honour comes great responsibility as well. A responsibility to steer the new society in the right direction, set the right values, systems and traditions. At the same time, this is indeed a great opportunity to start with a clean slate without the shackles of the past.

We will collectively have to ensure that we elect our office bearers purely on considerations of merit. Young colleagues will have to proactively come forward and be involved in the functioning of the society.

The scientific committee should be strengthened and should function independently in finalising a novel scientific program which will be beneficial to all members. This should be the core strength of our society and will automatically ensure a good attendance at our conferences.

Communicating with the members on a regular basis and inviting suggestions for improvement is very important in ensuring transparency and the involvement of all members.

Of late, the medical profession has been at the receiving end of adverse government decisions and journalistic and public wrath for all the wrong reasons. One of the important functions of our society should be to liaise with the Government, press and public to correct this impression. One of the first issues that our society has rightfully taken up is the issue of rationalising the requirements for EHS recognition. The aim is to also involve smaller eye hospitals in the care of EHS beneficiaries.

“ Be the change that you wish to see in the world”. - Mahatma Gandhi

“ They always say time changes things, but you actually have to change them yourself”- Andy Warhol.

We need to keep changing with time in order to progress. Change is essential. Let's do it together.

Dr Pradeep Swarup, MD
Hyderabad

INSTRUCTIONS TO AUTHORS

All manuscripts must be sent by email to any of the Editorial Board member.

Manuscripts details

Articles: Randomized controlled trials, intervention studies, studies of screening and diagnostic test, outcome studies, cost effectiveness analysis, case-control series, and surveys with high response rate come in this category. The limit of the text is 3000 words excluding about 30 references and structured abstract of 250 words.

Research methodology: This includes educative articles related to the conduct of research with word count up to 3000 and references up to 30.

Case reports: new/interesting/very rare cases can be reported. Cases with clinical significance or implications will be given priority. However, mere reporting of a rare case may not be considered. The limit is 1000 words excluding references and abstract with a maximum of 10 references.

Announcements of conferences, meetings, courses, and other items likely to be of interest to the readers should be submitted with the name and address of the person from whom additional information can be obtained.

Achievements of Institutions, Hospitals, Centres in Telangana or TOS Members should be submitted with the name and address of the person from whom additional information can be obtained.

The text of original articles should be divided into sections with the headings: **Abstract**, Key-words, Introduction, Material and Methods, Results, Discussion, References, Tables and Figure legends. For a brief report include **Abstract**, Key-words Introduction, Case report, Discussion, Reference, Tables and Legends in that order. The text should be in **MS Word** format. Use double spacing throughout.

Illustrations (Figures), Upload the images in JPEG format.

Figures should be numbered consecutively according to the order in which they have been first cited in the text.

The decision of the Editor and Editorial Board regarding suitability of submitted material for publication will be final.

Telangana Ophthalmological Society

Executive Committee



PRESIDENT

Dr G Hari Kishan

Kaman Road, Karimanagar
harikishangorityala@gmail.com
944062502



SECRETARY

Dr A Ravindra

Teja Eye Hospital, Hanamkonda
aitharaju.ravindra@gmail.com
9866426367



PRESIDENT-ELECT

Dr Manoj Chandra Mathur

Swarup Eye Centre, Medivision Hyderabad
Drmathur1961@hotmail.com
9393348827



ADVISOR

Dr NS Reddy

Banjara Hills, Hyderabad
nsrklb@yahoo.co.in
9246166611



TREASURER

Dr P Praveen

Kakatiya Eye Hospital, Hanamkonda
drpraveen@live.com
9652829652



JOINT SECRETARY

Dr Sreekumar

Asst Prof REH, Warangal
vaggusreekumar@gmail.com
9394058999



CHAIRMAN ARC

Dr V Rajalingam

Asst Prof SDEH, Hyderabad
rajalingamdr@yahoo.co.in
9848046378



CHAIRMAN SCIENTIFIC COMMITTEE

Dr Pravin Krishna

Cornea Consultant, LVPEI
pravin@lvpei.org
9849094245



EDITOR PUBLICATIONS

Dr Mallika Goyal

VR Consultant, Apollo Hospitals, Hyd
Drmallikagoyal1@gmail.com
9849270994

Contents

From President's & Secretary's Desk	4
APOC 2014 Award Winners	5
APOS-NS Reddy Post-Graduate Best Free Paper Medal 2014	5
Guest Article: Optical Coherence Tomography assessment of predescemet endothelial keratoplasty (PDEK) graft	6
Guest Article: ReLEx SMILE – The Future of Refractive Surgery	10
Keratoconus - A practical approach in diagnosis and management	14
Persistent fetal vasculature (PFV) with unusual finding of lenticular cyst	19
Chronic Progressive External Ophthalmoplegia: A Case Report	20
Clinical Profile of Ocular Surface Squamous Neoplasia: A Retrospective Case Series.	22
Intraocular Cysticercosis – A Differential Diagnosis For Leucocoria	24
Perfluorocarbon Liquid as short-term tamponade for posterior giant retinal tear	27
Plateau Iris	28
Retinal Optical Coherence Tomography	30
Minimally invasive eye lid & facial rejuvenation: An evolving world	35
Election for the post of Vice-President TOS (2015-16)	39
First Telangana State Ophthalmological Annual Conference	41

From The President's Desk



Dear Colleagues,

At the outset, let me thank all of you for the confidence and the support you have rendered to me and our team of office bearers in getting elected unopposed.

As you all know, the process of bifurcation was initiated by the AP State Executive as demanded by the two regions in June 2014 and culminated in the formation of two societies for the two regions at the Rajahmundry Conference.

Now a concerted effort is needed from all of us to strengthen our society by increasing our membership and taking part in all scientific activities.

I am happy to announce that the inaugural state conference will be held at Karimanagr on 20th & 21st June 2015 under the aegis of the Karimanagar Ophthalmological Association (KOA). As a member of KOA and President of TOS I invite you all for the Conference to enjoy our hospitality.

Wishing you a great future in our new State of Telangana,

With regards,

Dr G Hari Kishan, Karimanagar

From The Secretary's Desk



Dear Colleagues,

On behalf of our team of office bearers of the TOS, I would like to thank you all for your support in getting us elected unanimously. We promise to do our best in strengthening our society in all spheres.

After its ratification in Rajahmundry on October 24, 2014, TOS has registered its society at Hyderabad, opened a bank account and had the funds transferred as per norms. Our gratitude to Hony General Secretary Dr Nandkishore and other EC members of APOS for their efforts in the smooth transition. Development of the new website is underway.

Karimanagar Ophthalmological Association came forward to host the inaugural state conference on 20th & 21st June 2015 at Prathima Medical College.

I request our members to make all efforts to increase the TOS membership. Members of erstwhile APOS will continue to be members of TOS without any payment.

All your valuable suggestions, queries and inputs regarding any activities of the society and welfare of its members will be well taken.

Wishing you a great time in our new State of Telangana and hoping to see you at Karimanagr,

With regards,

Dr A Ravindra, MS, Warangal

APOS Gangadhar Quiz -2014

Winners: G S L Medical College, Rajahmundry

Dr Hasika Ravula, Dr Ravi Chandra and

Dr Lakshmi Spandana

Runners Up: Rangaraya Medical college, Kakinada

Dr Rohi Sowjanya, Dr Sarada Devi and Dr Afsar Sharmili

APOS-NS Reddy Post-Graduate Best Free Paper Medal 2014

Schwannoma of Lower Eye Lid: a rare differential diagnosis of eyelid swelling - Dr Hasika Ravula

APOS-NS Reddy Post-Graduate Second Best Free Paper Medal 2014

Anterior staphyloma with central corneal leucomatous opacity in a blind eye masking malignant melanoma of choroid - Dr Kavitha Mandalpu

APOS-Vengal Rao Medal 2014

A new clinical sign in parafoveal telangiectasia

- Dr Avinash Patangey

APOS-V Raghavachari Medal 2014

Treatment of Non-arteritic Ischaemic optic neuropathy (NAION) - Intra-vitreous Avastin versus oral corticosteroids - Dr Virender Sachdev

APOC 2014

Award



Winners

APOS-Swarup's Best Video Medal 2014

Re-operations in strabismus: How to make the second chance count? - Dr Virender Sachdeva

APOS- Srikiran Institute of Ophthalmology Best Poster Medal 2014

Two interesting cases of Internuclear Ophthalmoplegia - Dr L Karthika

Madiraju Ashok Session Best Paper

Treatment Outcome of Fungal Keratitis at a Tertiary Care Centre in Guntur District - Dr Madhuri Venigalla

APOS-NS Reddy Post-Graduate Best Free Paper Medal 2014



Schwannoma of Lower Eye Lid: A rare differential diagnosis of eyelid swelling

- Dr Hasika Ravula,

GSL Medical College, Rajahmundry

Aim: To report a rare case of histopathologically proven eyelid schwannoma which presented as a slowly growing mass in the lower lid.

Materials and methods: A 28 year old patient presented to the department of ophthalmology with a slowly growing mass in the right lower lid for 5 years. Examination revealed a 3 x 3 cm round, firm mass on the lateral aspect of the right lower lid causing narrowing of the right palpebral fissure. All the necessary investigations and imaging studies were performed. Complete surgical removal of the mass was carried out along with excision biopsy for histopathological study.

Results: Computed Tomography of orbits revealed a corresponding well defined iso -to hyperdense extraconal mass. Histopathological examination of the specimen revealed encapsulated mass made up of fascicles of spindle cells showing hypercellular and hypocellular areas and verocay bodies with intervening collagen suggestive of schwannoma.

Conclusion: Schwannomas are benign tumors of neuroectodermic origin with a predilection for spinal nerve roots, sympathetic, cervical and vagus nerves. There may be associated neurofibromatosis but solitary schwannoma at any site is not associated with this entity. Though eyelid schwannoma is extremely uncommon, it should be included as a differential diagnosis of well defined eyelid tumors.

Optical Coherence Tomography assessment of Predescemet Endothelial Keratoplasty (PDEK) graft

Dr Dhivya Ashok Kumar MD, FICO; Dr Amar Agarwal MS, FRCS, FRC Opth

Introduction

Predescemet's endothelial keratoplasty (PDEK), a recent modification of endothelial keratoplasty involved the transplantation of the predescemet's layer (Dua's layer) along with the descemet's membrane (DM) with endothelium. In this selective tissue transplantation, the predescemet's layer provided additional thickness to the thin DM. The predescemet's layer has been identified as a tough, fibrous layer about 10.15 ± 3.6 microns thick by Dua et al.¹ The principle advantages of the technique are easy intraoperative tissue handling and less injury to the donor harvested graft. The initial results showed good post operative outcomes and less surgical complications.² The technique inherited the basic advantages of early visual rehabilitation and lowered graft rejection similar to Descemet membrane endothelial keratoplasty (DMEK).^{3,4} The post operative graft position though clinically seen by slit lamp, high resolution spectral domain optical coherence tomography (SD-OCT) provides additional information in the configuration of endothelial grafts. In this chapter we have shown the post operative graft configuration using SD-OCT.

Surgical Technique

Predescemet's endothelial keratoplasty (PDEK)

A corneo-scleral disc with an approximately 2 mm scleral rim is dissected from the whole globe or obtained from an eye bank. A 30-gauge needle attached to a syringe is inserted from the limbus into the mid peripheral stroma (Figure 1 above left). Air is slowly injected into the donor stroma till a type 1 big bubble is formed (Figure 1 above left & central). Trephination is done along the margin of the big bubble. The bubble wall is penetrated at the extreme periphery and trypan blue is injected to stain the graft, which is then cut with a pair of corneo-scleral scissors and is covered with the tissue culture medium (Figure 1, above right).

Under peribulbar anesthesia, a trephine mark is made on the recipient cornea respective to the diameter of descemet membrane (DM) to be scored on the endothelial side. A 2.8 mm tunnel incision is made at 10 o'clock hours near the limbus. The anterior chamber (AC) is formed and maintained with saline injection or infusion. The margin of recipient DM to be removed is scored with a reverse Sinsky hook and then peeled (Fig 1 middle left & central). Donor lenticule (endothelium-DM-pre Descemet's layer) roll is inserted in the custom made injector (Figure 1 middle, right) and is injected in a controlled fashion into the AC (Figure 1 lower, left). The donor graft is oriented

endothelial side down and positioned on to the recipient posterior stroma by careful, indirect manipulation of the tissue with air and fluid (Figure 1 lower central). Once the lenticule is unrolled, an air bubble is injected underneath the lenticule to lift it towards the recipient posterior stroma (Figure 1 lower right). The AC is completely filled with air for the next 30 minutes followed by an air-liquid exchange to pressurize the eye. Eye speculum is finally removed and AC is examined for air position. The patient is advised to lie in a strictly supine position for next 3 hours.

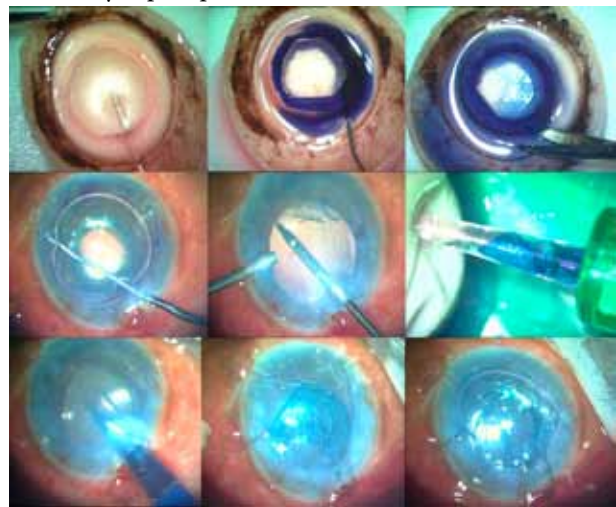

Figure 1: Predescemet's endothelial keratoplasty (Above, left) Type 1 bubble is formed in the donor cornea by injecting air via 30g needle (Above, central) Trypan blue is injected into the bubble. Trephination was done and the graft is cut with a pair of corneal scissors (Above, right). (Middle left & central) The margin of recipient descemet membrane to be removed is scored with a reverse Sinsky hook and then peeled. Donor lenticule roll is inserted in the custom made injector (Middle right) and is injected in a controlled fashion into the AC (Lower left). The donor lenticule is positioned on to the recipient posterior stroma and unrolled with air and fluid (lower central). Finally an air bubble is injected underneath the lenticule to lift it towards the recipient posterior stroma and followed by air-fluid exchange (Lower right).

Spectral domain OCT

Post operative SD-OCT scans were performed by experienced examiner and the scans were evaluated by expert ophthalmologists. Anterior segment 5 line raster pattern in axis of 0-1800 and 90-2700 was used. The raster scan had five lines (length 3mm) and 250 μ m distance in between the lines. The scan was centered at the corneal vertex for central 3mm scan. Additional inferior, temporal, nasal and superior positional scans were also taken. Graft thickness was measured with the tool caliper in the SD-OCT

in microns. Graft detachment was graded as group I when there was completely attached grafts or with a minimal edge detachment; group II: graft detachments less than 1/3 of the graft surface area, not affecting the visual axis; group III: graft detachments more than 1/3 of the graft surface area; and group IV: completely detached grafts. Epithelial thickness and recurrence of bulla were noted. Graft host junction was visualized for interface opacification. Graft split is defined as the separation of predescemet's layer and descemet's membrane. Postoperative central corneal thickness (CCT) was also measured in all follow ups. Twelve eyes of 12 patients with mean age 65 ± 3.8 years were evaluated. There were 9 females and 3 males. The donor age ranged from 1 to 56 years. The graft size ranged from 7.5mm to 8mm. All the eyes had preoperative pseudophakic bullous keratopathy as the indication for endothelial transplantation.

PDEK graft in OCT

The mean graft thickness in PDEK was 37.3 ± 3.5 microns (range 32 to 44μ). The graft undergoes minimal dehydration in the post operative period. The mean GT on day 7, day 30 and day 90 was $35.5 \pm 3.4 \mu$ (32 to 40μ), $33 \pm 1.8 \mu$ (32 to 36μ) and $30.3 \pm 2.6 \mu$ (28 to 36μ) respectively. There was significant difference in the GT over the time period (Friedman test, $p=0.000$) (Figure 2). There was no significant difference ($p=1.000$) between the central (3mm) and peripheral (4-6mm) graft thickness.

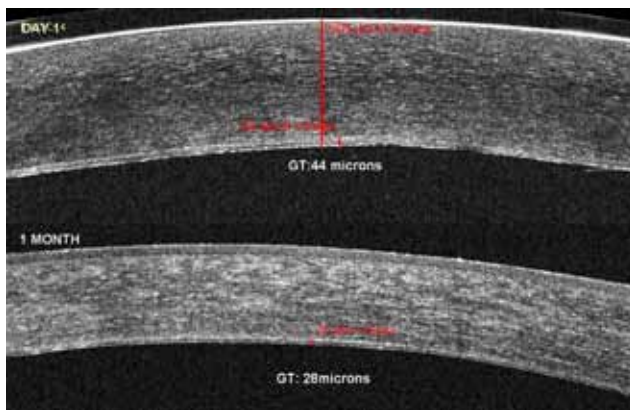


Figure 2: Graft thickness shows significant reduction from the immediate post operative period to one month.

Graft was well adhered (Figure 3) in 9 out of 12 eyes on day one. Two eyes had group II detachment (Figure 4) and one eye had group III graft detachment. One eye with grade III detachment underwent air injection. Graft was well apposed in the post air injection day one; however there was redetachment on day 12 and rebubbling was done subsequently. In group I eyes with well adhered graft, small shallow peripheral detachment was seen in the inferior (2 eyes) and nasal quadrant (1 eye). The mean detachment depth was $24.6 \pm 8.3 \mu$. Descemet folds were noted in 2 eyes on day one which resolved on day 7 with medical management and supine position. Smooth concave configuration of posterior cornea was obtained in all the eyes by 1 month.

None of the eye had complete graft detachment or lenticule drop.

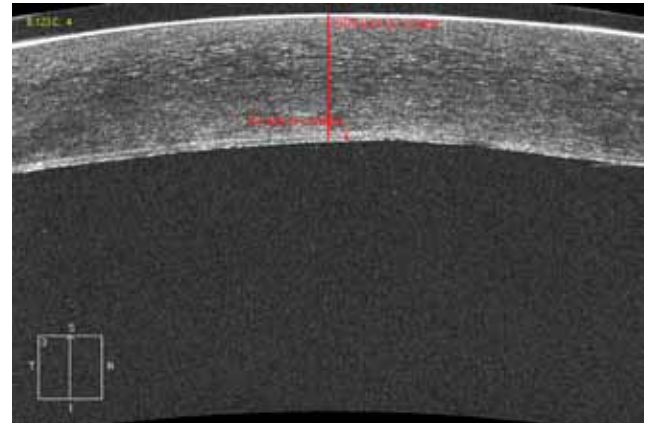


Figure 3: Day one postoperative image of well adhered graft seen in spectral domain optical coherence tomography.

Eleven out of 12 eyes had smooth graft host interface. One eye had minimal interface haze by postoperative 1 month. After a course of intense steroid treatment, the graft host interface haze decreased in one eye (Figure 5). Separation of graft into 2 linear hyperreflective lines was seen in OCT in 2 eyes. The posterior layer was 16μ and the anterior one was 12μ . Both the eyes had mild corneal edema on day one which resolved with strict supine position and medical management.

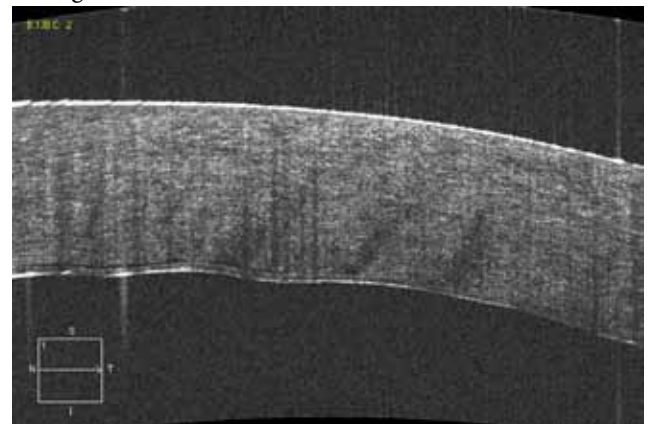

Figure 4: Day one postoperative image showing shallow graft detachments in spectral domain optical coherence tomography.

All eyes had central epithelial defect on postoperative day one. Epithelial healing was complete in all eyes by 48 hours. The mean epithelial thickness was $44.4 \pm 9.8 \mu$ on the first week and reduced to $37.5 \pm 6.2 \mu$ in the last follow up. There was significant reduction in the thickness ($p=0.003$) over the time period. There was no difference in the central and peripheral epithelium in 11 eyes. The mean day one postoperative CCT was $612 \pm 46.4 \mu$. There was significant resolution of corneal edema by day 7 ($p=0.001$). Grade 3 cellular reaction was seen in one eye and one eye had grade 4 fibrinous reaction. Shallow detachment was seen in the eye with fibrin. Intense steroid treatment attained good graft adherence by 2 weeks.

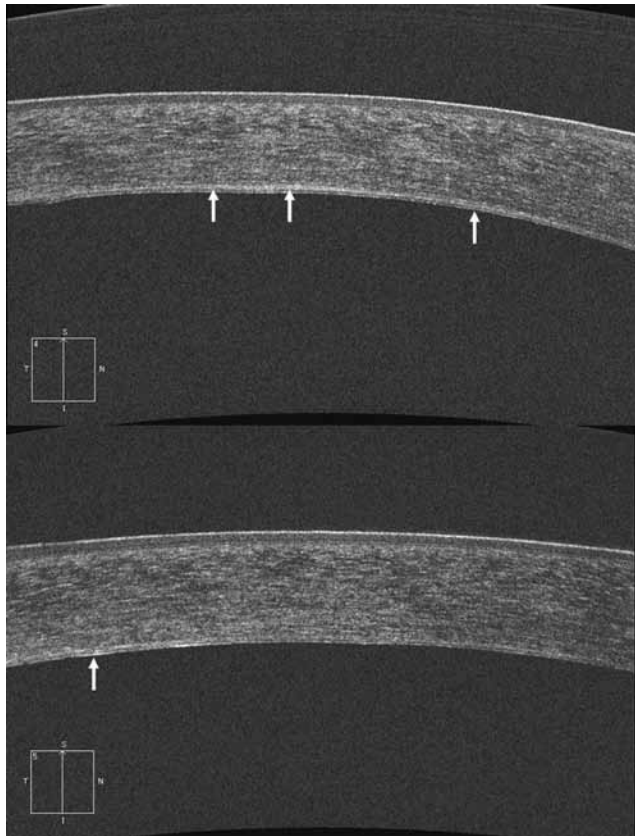


Figure 5: Spectral domain optical coherence tomography showing graft interface opacification (above, arrow) and resolution after treatment with intense steroids (below, arrow).

Correlations & associations

There was no significant correlation between the graft thickness and the best corrected vision at day 1 ($p=0.409$) and day 90 ($p=0.661$). There was no correlation between the mean CCT reduction and the graft thickness reduction from day 1 to day 90 ($p=0.645$, $r=0.149$). There was no correlation between the corneal edema and graft thickness on day 1 ($p=0.374$, $r=0.282$). There was no association between the corneal thickness on day 1 and the graft detachment (Chi square test, $p=0.285$). There was no association between the graft thickness on day 1 and the graft detachment (Chi square test, $p=0.167$). There was strong association with graft adherence and best corrected visual acuity (Chi square, $p=0.007$). Eyes with early detachment showed poorer visual outcome.

OCT in endothelial keratoplasty

Anterior segment OCT has been used in DMEK for predicting the post operative graft adherence.⁵ It has also been used for intraoperative graft positioning.⁶ In our study we have shown the behavior of PDEK graft in vivo in the post operative follow up. Yeh et al studied the predictability of OCT scan for graft attachment in DMEK.⁵ They noticed that the initial one hour showed the best predictive value in DMEK graft adherence. Because of graft edema and stromal edema in the immediate post operative period, it might be difficult to localize detachments clinically in slit lamp. Therefore the anterior segment OCT has been utilized to

visualize those endothelial grafts (DSAEK or DMEK) under such situations. Though time domain anterior segment OCT^{6,7,8} has been used for evaluating graft status after endothelial keratoplasties like DSAEK and DMEK; there are no study on the evaluation of grafts by spectral domain OCT. Clinically undetectable detachments can also be localized by spectral domain OCT because of the higher resolution (5 microns).

PDEK graft versus other endothelial grafts

The mean central graft thickness in ultrathin Busin graft was 78.28 ± 28.89 microns at 3 months postoperative period.⁹ Shousha et al reported the thickness of normal descemet membrane in elderly to be about 16 ± 2 microns (range 13-20 μ) in ultra high resolution OCT.¹⁰ The mean graft thickness on our study was 37.3 ± 3.5 microns and it got stabilized by 3 months. From our study we noticed that the PDEK grafts are thicker than DMEK grafts and thinner than ultra thin DSAEK grafts. The PDEK grafts were uniform with no difference in the thickness from central to periphery as seen in OCT. Graft adherence has been a single important factor for better functional outcome after successful endothelial keratoplasty.^{11,12} Graft detachment has been described as the common complication after endothelial keratoplasty techniques like DMEK and DSAEK.¹¹⁻¹⁴ Though thinner grafts are more susceptible for incomplete graft adherence after primary positioning; early visual recovery may be possible only with thin graft.¹⁵ Pre descemet endothelial keratoplasty graft has the advantage of thinner grafts similar to DMEK; which can aid in easy intraoperative manipulation and at the same time postoperative adherence.

The two main factors which interfere with graft attachments are the intracorneal pressure and the interposition¹⁵ and these factors are necessary for the PDEK grafts as well. Precut donor tissue over hydration, stromal edema (both donor or recipient) and irregular interface prevents graft adherence. In our study, the graft was well adhered in 75% of the eyes. There was no eye with total graft detachment or lenticule drop in the anterior chamber.

The possibility of separation of corneal layers by pneumatic dissection has been proven and it has been technically easier.^{17,18} Hence the preparation of PDEK lenticule is not difficult in the present clinical setup. The biggest challenge faced in DMEK is the tissue loss in preparation and post operative attachment. Price et al reported that the recent advances in instrumentation and technique have reduced the learning curve of DMEK.¹⁹ However it has been known that DMEK provides faster visual recovery without interface opacification.²⁰ The absence of interface reaction is one of the advantage in DMEK grafts as compared to DSAEK grafts. Similarly in PDEK grafts analysis in OCT, there was

less or no interface opacification in the postoperative period (Figure 6).

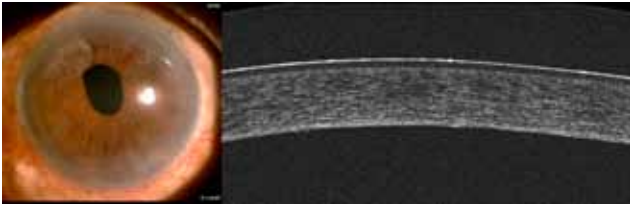


Figure 6: Clinical photograph (left) and Spectral domain optical coherence tomography (right) after 6 months post predescemet's endothelial keratoplasty with no interface haze.

Dua et al reported the absence of keratocytes in the central region of the predescemet's layer and this layer may be the factor that can potentially contribute to reduced haze (Figure 7), as air cleavage creates a smooth plane and lessened keratocyte activity.¹ The split in the graft which was seen in 2 eyes resolved spontaneously with strict supine position. However those 2 eyes with graft split did not have the graft detachment or corneal edema in the post operative period. Nevertheless the additional predescemet's layer attached to the DM is expected to provide splinting effect to the DM in the graft and at the same time preserve the early visual rehabilitation nature of DMEK.

Figure 7 Awaited from Author

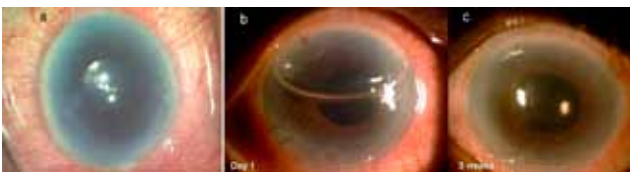

Figure 7: Good post operative corneal clarity was seen after PDEK (a: preop, b: immediate, c: 3 weeks)

REFERENCES

- Dua HS, Faraj LA, Said DG, Gray T, Lowe J. Human corneal anatomy redefined: a novel pre-Descemet's layer (Dua's layer). *Ophthalmology*. 2013 Sep;120(9):1778-85.
- Agarwal A, Dua HS, Narang P, Kumar DA, Agarwal A, Jacob S, Agarwal A, Gupta A. Pre-Descemet's endothelial keratoplasty (PDEK). *Br J Ophthalmol*. 2014 Mar 27. doi: 10.1136/bjophthalmol-2013-304639. [Epub ahead of print]
- Melles GR, Ong TS, Ververs B, van der Wees J. Descemet membrane endothelial keratoplasty (DMEK). *Cornea*. 2006 Sep;25(8):987-90.
- Tourtas T, Laaser K, Bachmann BO, Cursiefen C, Kruse FE. Descemet membrane endothelial keratoplasty versus descemet stripping automated endothelial keratoplasty. *Am J Ophthalmol*. 2012 Jun;153(6):1082-90.
- Yeh RY, Quilendrino R, Musa FU, Liarakos VS, Dapena I, Melles GR. Predictive value of optical coherence tomography in graft attachment after Descemet's membrane endothelial keratoplasty. *Ophthalmology*. 2013 Feb;120(2):240-5.
- Steven P1, Le Blanc C, Velten K, Lankenau E, Krug M, Oelckers S, Heindl LM, Gehlsen U, Hüttmann G, Cursiefen C. Optimizing descemet membrane endothelial keratoplasty using intraoperative optical coherence tomography. *JAMA Ophthalmol*. 2013 Sep;131(9):1135-42.
- Tan GS1, He M, Tan DT, Mehta JS. Correlation of anterior segment optical coherence tomography measurements with graft trephine diameter following descemet stripping automated endothelial keratoplasty. *BMC Med Imaging*. 2012 Jul 23;12:19.
- Moutsouris K, Dapena I, Ham L, et al. Optical coherence tomography, Scheimpflug imaging and slit-lamp biomicroscopy in the early detection of graft detachment after Descemet membrane endothelial keratoplasty. *Cornea* 2011;30:1369-75.
- Busin M1, Madi S, Santorum P, Scorgia V, Beltz J. Ultrathin descemet's stripping automated endothelial keratoplasty with the microkeratome double-pass technique: two-year outcomes. *Ophthalmology*. 2013 Jun;120(6):1186-94.
- Shousha MA1, Perez VL, Wang J, Ide T, Jiao S, Chen Q, Chang V, Buchser N, Dubovy SR, Feuer W, Yoo SH. Use of ultra-high resolution optical coherence tomography to detect in vivo characteristics of Descemet's membrane in Fuchs' dystrophy. *Ophthalmology*. 2010 Jun;117(6):1220-7.
- Dirisamer M, van Dijk K, Dapena I, et al. Prevention and management of graft detachment in Descemet membrane endothelial keratoplasty. *Arch Ophthalmol* 2012;130:280-91.
- Guerra FP, Anshu A, Price MO, et al. Descemet's membrane endothelial keratoplasty: prospective study of 1-year visual outcomes, graft survival, and endothelial cell loss. *Ophthalmology* 2011;118:2368-73.
- Shih CY1, Ritterband DC, Rubino S, Palmiero PM, Jangi A, Liebmann J, Ritch R, Seedor JA. Visually significant and nonsignificant complications arising from Descemet stripping automated endothelial keratoplasty. *Am J Ophthalmol*. 2009 Dec;148(6):837-43.
- Suh LH1, Yoo SH, Deobhakta A, Donaldson KE, Alfonso EC, Culbertson WW, O'Brien TP. Complications of Descemet's stripping with automated endothelial keratoplasty: survey of 118 eyes at One Institute. *Ophthalmology*. 2008 Sep;115(9):1517-24.
- Dapena I, Ham L, Melles GR. Endothelial keratoplasty: DSEK/DSAEK or DMEK--the thinner the better? *Curr Opin Ophthalmol*. 2009 Jul;20(4):299-307.
- Busin M1, Madi S, Santorum P, Scorgia V, Beltz J. Ultrathin descemet's stripping automated endothelial keratoplasty with the microkeratome double-pass technique: two-year outcomes. *Ophthalmology*. 2013 Jun;120(6):1186-94.
- Anwar M, Teichmann KD. Big-bubble technique to bare Descemet's membrane in anterior lamellar keratoplasty. *J Cataract Refract Surg* 2002;28:398-403.
- Busin M1, Scorgia V, Patel AK, Salvalaio G, Ponzin D. Pneumatic dissection and storage of donor endothelial tissue for Descemet's membrane endothelial keratoplasty: a novel technique. *Ophthalmology*. 2010 Aug;117(8):1517-20.
- Price MO1, Price FW Jr. Descemet's membrane endothelial keratoplasty surgery: update on the evidence and hurdles to acceptance. *Curr Opin Ophthalmol*. 2013 Jul;24(4):329-35.
- Ham L, Balachandran C, Verschoor CA, et al. Visual rehabilitation rate after isolated Descemet membrane transplantation: descemet membrane endothelial keratoplasty. *Arch Ophthalmol* 2009; 127:252-255.

Correspondence



Prof Amar Agarwal MS, FRCS, FRCOphth
Dr. Agarwal's Eye Hospital and
Eye Research Centre
19 Cathedral Road, Chennai-600 086, India
Tel- + 91 44 2811 6233, Fax- + 91 44 2811 5871
E-Mail- Dragarwal@Vsnl.Com

ReLex SMILE – The Future of Refractive Surgery

Dr Mahipal S Sachdev, MD ; Dr Ritika Sachdev, MS; Dr Gitansha Sachdev, MS, FICO

Refractive Lenticule extraction (ReLex) is the most recent development in the field of keratolenticular refractive procedures¹. The refractive lenticule cut is performed using the state of the art Femtosecond laser, following which it is extracted through a corneal incision. Small incision Lenticule Extraction (SMILE) has become a preferred alternative to LASIK for myopic correction in Europe and Asia and is currently showing promising results in the third phase of clinical trials for approval by the US Food and Drug Administration.

Travelling the path

In the past myopic correction involved the removal of a stromal lenticule using a mechanical microkeratome. Although introduced by Barraquer² in the 1950s, microkeratomes reached a level of refinement in the late 1980s. However because of increased associated complications, lamellar keratoplasty techniques remained niche techniques to treat high myopia and never became part of the ophthalmic mainstream.

The excimer laser was introduced in 1983 and was first used for refractive correction in 1988. Photorefractive keratectomy involved mechanical epithelial debridement with subsequent laser assisted corneal reshaping. It quickly became the procedure of choice to treat refractive errors following US Food and Drug Administration approval in 1995. Major disadvantages of this procedure included patient discomfort following epithelial debridement, delayed visual recovery, corneal haze and regression.

Today, despite significant improvements in laser ablation profiles, medication and wound-healing modulation regimens, and surgical technique, excimer laser PRK is performed on less than 20% of all refractive surgery patients.

In the early 1990s, the work of Burratto et al³ and Pallikaris et al⁴ married the concept of ALK with the excimer laser into a procedure known as laser-assisted in situ keratomileusis (LASIK). Lasik involved the construction of a 130 to 160 microns thick hinged corneal flap using a microkeratome followed by excimer laser assisted stromal ablation. The flap was then refloated back onto the corneal stroma and allowed to heal in place without sutures. Flap associated complications include buttonhole flaps, incomplete flaps, irregular flaps and flap displacements. In addition, mechanical microkeratomes sometimes make flaps that are inadvertently too thick, resulting in post LASIK ectasias⁵⁻⁶. The drawbacks associated with

microkeratomes were overcome by the construction of flaps using femtosecond laser⁷. However, there is a need for two lasers to complete the procedure – the femtosecond laser to make the flap and the excimer laser to perform the laser ablation of the refractive lenticule. This leads to significant extra capital and maintenance costs and the consumable and license fees for both the lasers. There is also significant workflow disturbance within the laser suite, with the surgeon and the patient moving from one laser to another.

The femtosecond laser can be used to carve out a lenticule within the corneal stroma. The lenticule can then be extracted from within the corneal stroma, either by creating and lifting a hinged flap similar to LASIK or by extricating it using a small incision in the cornea. These techniques of femtosecond lenticule extraction are known as femtosecond lenticule extraction (FLEX) and small-incision lenticule extraction (SMILE) respectively. Both techniques represent all-in-one femtosecond laser refractive surgery because they represent novel integrated surgical techniques to perform corneal laser surgery in a single step and need a single laser to perform refractive surgery and have various clinical, practical, and economic advantages over the more traditional two lasers.

Selection criteria

- Age – The patient should be older than 18 years of age
- Refractive error- Myopic error of upto -10 D spherical equivalent, with or without an astigmatism of upto -5 D and a stable refraction for over a year. ReLex SMILE is currently not available for hyperopic correction.
- Corneal topography - To rule out forme fruste keratoconus, pellucid marginal degeneration and posterior keratoconus.
- Pachymetry – The procedure is contraindicated in corneas thinner than 480 microns or in cases where the residual corneal thickness postoperatively is likely to be less than 400 microns.
- Ocular history – Contraindicated in patients with lenticular changes, glaucoma or other pre existing ocular diseases. Retinal breaks or holes if any should be treated prior to the procedure.

VisuMax Laser System

ReLEX SMILE procedure is performed using the state of the art VisuMax Femtosecond laser⁸. The VisuMax software calculates the thickness of lenticule required for refractive correction and the femtosecond laser creates a refractive lenticule with a high degree of precision.

Procedure

The procedure is performed under topical anesthesia. The patient's eye is cleaned and draped using all aseptic precautions. A standard speculum is used to keep the eye open. A joystick attached to the movable bed is used to align the patient's eye to the curved contact glass interface during the laser procedure, and repositioned under the integrated surgical microscope during the phase of surgical manipulation.

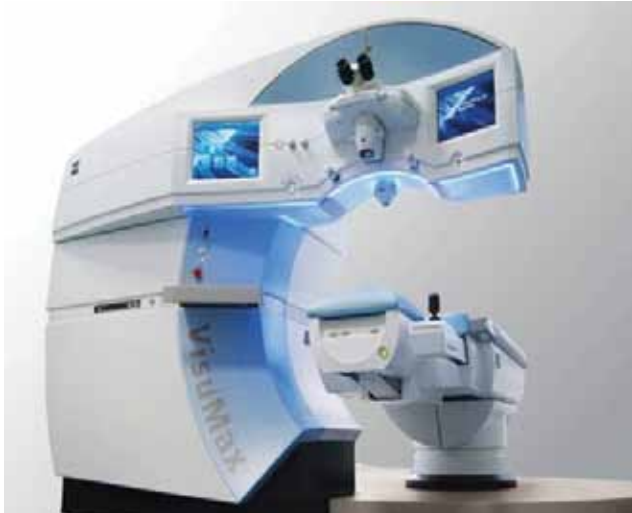

Figure 1: VisuMax Laser System

A sterile curved contact glass is attached onto the laser system optical aperture. The patient is positioned some distance below it and asked to focus on a blinking light and maintain fixation. Following proper centration and adequate placement of the contact glass on the patient's eye, suction is initiated to hold the cornea against the contact glass interface.

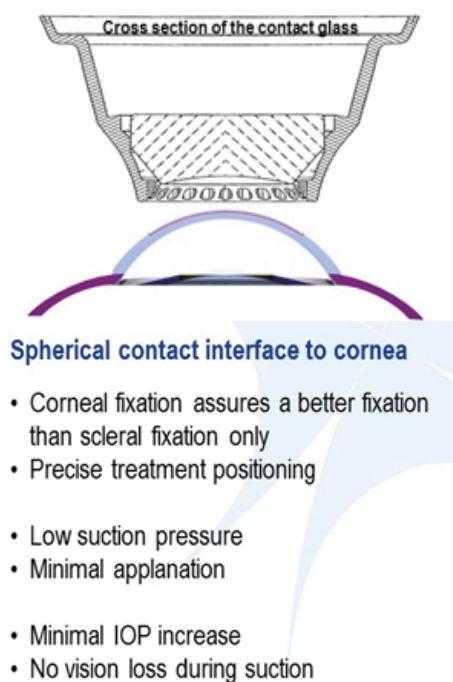


Figure 2: The innovative corneal interface concept

The delivery of femtosecond laser pulses is initiated once adequate suction is achieved. Each laser pulse with a typical energy of less than 200 nJ converts a small volume of corneal tissue into a gas bubble, thereby disrupting the cornea at its respective position. Several millions of such pulses delivered with a pulse repetition rate of 500 KHz, create a tissue disruption plane within the corneal stroma. The VisuMax laser system is capable of creating a 3-dimensional free-form incision plane anywhere within the cornea, with a precise shape. The entire procedure takes less than 23 seconds, practically independent of the refractive error to be corrected.


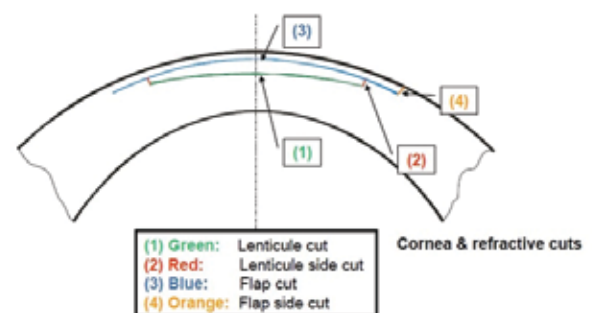


Figure 2: Photodisruption by femto laser

The various tissue disruption planes created by the laser are as follows:

- (1) The posterior surface of the refractive lenticule with a pre-programmed diameter ranging from 5 to 7 mm based on the optical zone selected.
- (2) The 360-degree circular length vertical edge of the refractive lenticule, with a depth equivalent to the thickness of the edge of the lenticule. The minimal thickness of the lenticule edge is 10 to 15 microns allowing easy surgical manipulation.
- (3) The anterior surface of the refractive lenticule, which is extended by about 0.5mm beyond the optical zone desired. The anterior surface can be programmed to be 100 microns or below the corneal surface, similar to the flap thickness in LASIK.
- (4) The flap side cut incision at an angle of 30 to 50 degrees from the corneal surface, with a depth up to the edge of the anterior part of the lenticule. The incision is generally created superiorly or superotemporally to preserve the nasal and temporal nerve arcades and to provide surgical convenience.



Following completion of the femtosecond laser (treatment mode) the suction automatically turns off. The patient's eye is repositioned under the microscope (observation mode). The side cut incision is opened up using a small sharp tipped instrument. Small pockets are created both in the anterior and posterior planes using a small sharp spatula. A blunt spatula is then used to separate the anterior and the posterior planes and to free the edges of the lenticule. Microforceps are inserted through the side cut to grasp and extract the lenticule from the corneal stroma. APVA spear is used to wick off excess fluid from the side cut incision. After 30 seconds, the speculum is removed. Both eyes can be treated in a single sitting.

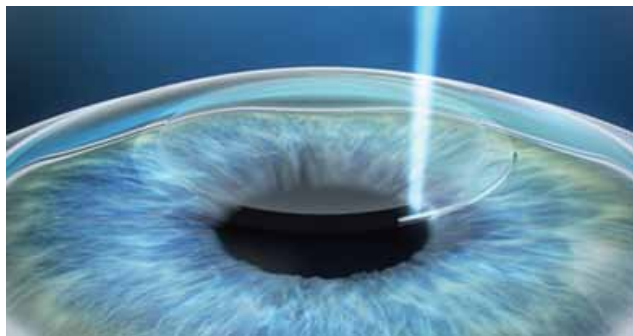


Figure 3: Tissue disruption planes

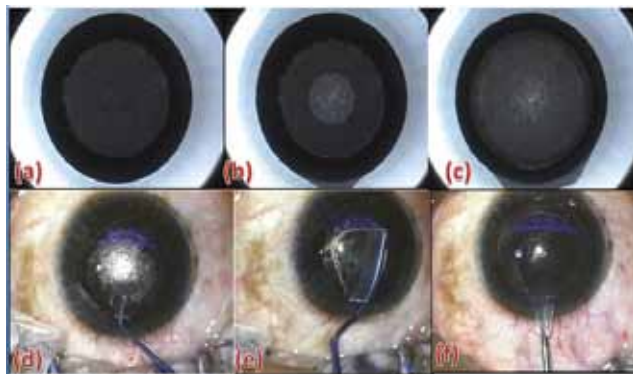


Figure 4: Surgical steps

Femto Laser assisted

- (a) Posterior tissue disruption plane (Lenticule cut)
- (b) Anterior tissue disruption plane (Flap cut)
- (c) Superior flap side cut incision

Manual

- (d) Delineation of planes
- (e) Dissection of planes
- (f) Lenticule removed.

Complications

1. Loss of contact between the glass interface and the cornea, resulting in suction loss may occur due to sudden eye or head movement. In such a situation the VisuMax automatically goes into restart mode. Depending on the stage at which the suction loss occurs, the restart mode repeats both femtosecond passes, only the flap pass, or only the side cut. The

general challenge in this situation is redocking of the contact glass interface to the eyewhile retaining centration, particularly when gas bubbles obscure the pupil. In our experience, repeating the treatment immediately is convenient and has no adverse effects on the postoperative results.

2. Incorrect dissection of the posterior plane prior to the anterior plane results in adherence of the anterior lenticule to the overlying flap. In such a case one can convert to FLE_x by repeating a 280 to 330 degree side cut incision.
3. A fine scarring is observed at the flap edge or the lenticule edge in a number of patients. However, it lies outside the pupillary zone and is visually insignificant.
4. Symptoms of dry eye may be observed postoperatively, however the occurrence is less as compared to that with conventional LASIK⁹. These symptoms are found more commonly in preoperative chronic contact lens users.
5. Enhancements following the procedure if required are carried out by excimer laser PRK or by lifting the flap and ablating the stroma using excimer laser.

Vertical gas breakthrough¹⁰, transient light sensitivity syndrome¹¹, or rainbow glare¹² are almost never seen.

Advantages over Femto-LASIK

1. There are economic, clinical and workflow advantages of performing only femto procedures like ReLE_x SMILE over Femto-LASIK in terms of saving on capital costs, maintenance costs and consumable costs.
2. Photodisruptive mechanism in ReLE_x, unlike ablative mechanism of excimer laser is independent of factors like corneal hydration, temperature, atmospheric humidity and depth of stromal ablation.
3. Increased refractive predictability over excimer laser particularly for higher refractive errors.
4. With femtosecond laser, the peripheral loss of fluence is not a factor at all, and no compensation needs to be carried out. So the amount of tissue required per diopter of treatment is smaller than that required with an excimer laser which compensates for the peripheral energy loss.
5. Reduced amount of energy is applied on to the cornea. Moreover the heat generated by an excimer laser is in a relatively shorter period resulting in adverse effects on corneal healing.
6. Reduced number of corneal nerves are severed due to smaller flap diameter and side cut incision, thereby reducing the incidence of postoperative dry eye.
7. Reduced risk of flap displacement.
8. The small side cut incision heals relatively faster causing less patient discomfort.
9. Finally, the procedure saves working time as there is no

time loss in switching patients from one laser to another.

REFERENCES:

1. Rupal Shah, MS, Samir Shah, MTech, MS, and Hartmut Vogelsang. All-in-One Femtosecond Laser Refractive Surgery Tech Ophthalmology 2011;9: 114-21)
2. Barraquer JI. The history and evolution of keratomileusis. Int Ophthalmol Clin. 1996 Fall;36(4):1-7.
3. Buratto L, Ferrari M, Rama P. Excimer laser intra stromal keratomileusis. Am J Ophthalmol. 1992;113:291-95.
4. Pallikaris IG, Papatzanaki ME, Siganos DS, et al. A corneal flap technique for laser in situ keratomileusis: human studies. ArchOphthalmol. 1991;109:1699-1702.
5. Binder PS. Ectasia after laser in situ keratomileusis. J Cataract Refract Surg. 2003;29:2419-429.
8. Binder PS. Analysis of ectasia after laser in situ keratomileusis: risk factors. J Cataract Refract Surg. 2007;33:1530-38.
7. Ratkay-Traub I, Ferincz IE, Juhasz T, et al. First clinical results with the femtosecond neodymium-glass laser in refractive surgery. J Refract Surg. 2003;19:94-103.
8. Blum M, Kunert K, Gille A, et al. LASIK for myopia using the Zeiss VisuMax femtosecond laser and MEL 80 excimerlaser. J Refract Surg. 2009;25(4):350-56.
9. Sekundo W, Kunert K, Russmann C, et al. First efficacy and safety study of femtosecond lenticule extraction for the correction of myopia - Six Month Results. J Cataract Refract Surg. 2008;34:1513-20.
10. Seider M, Ide T, Kymionis G, et al. Epithelial breakthrough during Intralase flap creation for laser in situ keratomileusis. J Cataract Refract Surg. 2008;34:859-63.
11. Stonecipher KG, Dishler J, Ignacio TS, et al. Transient lightsensitivity after femtosecond laser flap creation: clinical findings and management. J Cataract Refract Surg. 2006;32:91-94.
12. Bamba S, Karolinne R, Ramos-Esteban J, et al. Incidence of rainbow glare after laser in situ keratomileusis flap creation with a 60 kHz femtosecond laser. J Cataract Refract Surg. 2009;35:1082-86.

Correspondence:



Dr Mahipal Sachdev
Centre for Sight, B5/24,
Safdarjung Enclave
New Delhi
Email:
drmahipal@gmail.com



Dr Ritika Sachdev MS
Centre for Sight, B5/24,
Safdarjung Enclave
New Delhi
Email:
ritikasachdev@gmail.com



Dr Gitansha Sachdev
MS, FICO
Centre for Sight, B5/24,
Safdarjung Enclave
New Delhi



Telangana Ophthalmological Society Formation Celebrations

November 2, 2014 at Hotel Ashoka, Warangal



Chief Guest was Dr T Rajaiah, the then Dy. CM & Minister of Health, Govt of Telangana

This was preceded by a CME where speakers were Dr Mallika Goyal, Dr Rishi Swarup and Dr Maaz Mohiuddin.

Keratoconus - A practical approach to diagnosis and management

Dr Nitesh Narayen MS; Dr MS Sridhar MD

Keratoconus is a corneal thinning disorder in which the inferior paracentral cornea thins and protrudes forwards (Figure 1). Though keratoconus commonly involves inferior paracentral cornea, cases of superior keratoconus are also available in literature. The reported incidence of keratoconus is 1:1000 to 1:20000.¹ Keratoconus seems to be commoner in Asians where it is of early onset and severe. The onset is usually during the second decade.² The disease affects the quality of vision and hence causes reduced quality of life.

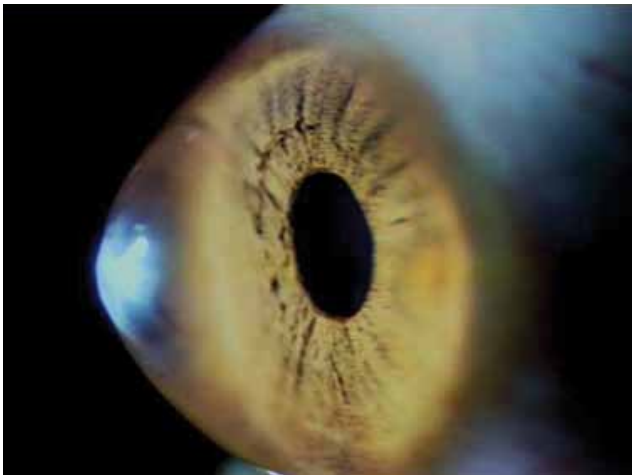


Figure 1. Keratoconus with ectasia of cornea and apical scarring.

PRESENTING SYMPTOMS

Blurred vision and frequent changes of spectacle power are the common presenting symptoms.

EYE RUBBING

In addition to heredity, there seems to be an association of eye rubbing and development of keratoconus. It looks like eye rubbing is also involved with progression of keratoconus and development of acute corneal hydrops.³

Various reasons for eye rubbing in keratoconus patients are as follows

- 1) Some patients of keratoconus say they rub their eyes as they felt it would improve their vision.
- 2) Patients of vernal keratoconjunctivitis and severe ocular allergy rub their eyes vigorously and later develop keratoconus. (Figure 2).

In patients with severe ocular allergy, topographic indices are found to be abnormal.⁴ Any patient with myopic astigmatism should be followed up carefully for the development of keratoconus if they have severe allergy.

- 3) Lid margin disease – patient rub their eye because of

irritation and itching.

- 4) Patients with Leber's Congenital Amaurosis develop keratoconus as these patients rub their eyes to stimulate their retina.
- 5) Down's Syndrome patients rub their eyes as they are mentally retarded.
- 6) Oculodigital reflex. We have seen a child with acute corneal hydrops in left eye, right eye being absolutely normal. History revealed, child had habit of sucking the left thumb and whenever she sucks her thumb, she keeps on pressing the left eye with index finger.

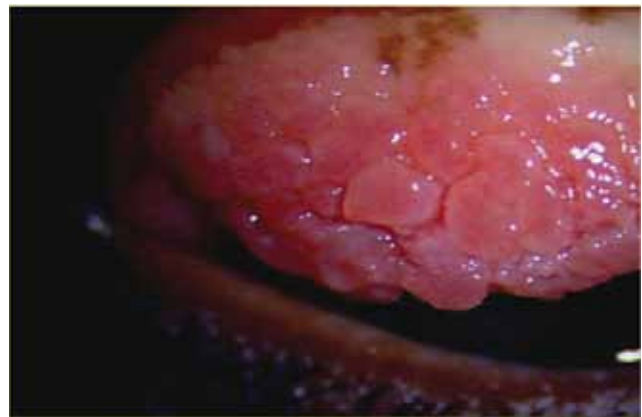


Figure 2. A case of severe allergy which can predispose to Keratoconus.

CLINICAL FEATURES

Any myopic astigmatism which is increasing or vision not improving to 6/6 or 20/20 should be suspected to have Keratoconus.

Signs

- a) Refraction: 1). myopic astigmatism 2). scissors reflex because of areas of myopic and hyperopic refraction
- b) Thinning of inferior paracentral cornea
- c) Protrusion or ectasia of inferior cornea
- d) The area of thinned ectatic cornea is in the form of cone. Cones in keratoconus can be round/nipple shaped, oval/sagging and global if the entire cornea is involved. In oval or a sagging kind of cone, a large area of ectatic thin cornea touching the limbus may be seen. In global type, the entire cornea is conical.⁶
- e) Vogt's stria- these are stria or folds just in front of Descemet's membrane. They disappear on pressure over the eye.
- f) Apical sub-epithelial and Descemet's level scarring.
- g) Increased visibility of endothelial reflex.
- h) Prominent corneal nerves.
- i) Fleischer's ring is deposit of iron in the base of the

cone. Fleischer's ring is important for corneal surgeons as entire thinned cornea needs to be excised during surgery. If residual thinned cornea is left, then significant astigmatism may remain following surgery requiring glasses or contact lens after surgery.

- h) Munson's sign – On looking down, the cone divides the lower lid margin. (Figure 3)

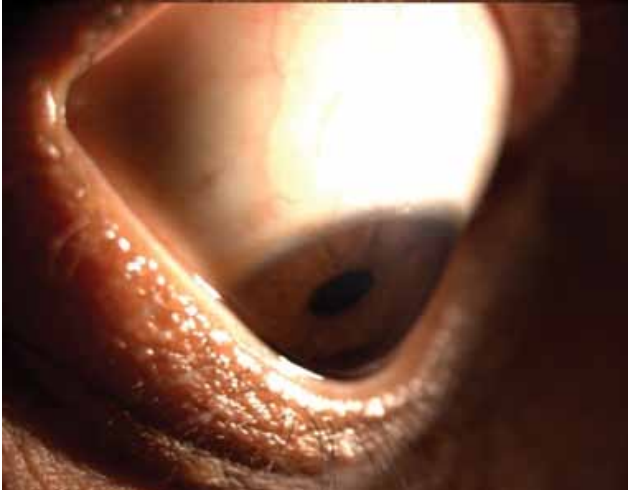


Figure 3. A case of Keratoconus showing Munson's sign.

- i) Rizzuti sign – When a torch light is thrown from the temporal side, in a normal cornea the nasal and the temporal cornea is equally illuminated. In a conical Cornea, the light focused by the cone is seen as a vertical line on the nasal iris.
- j) Keratometry – Steep cornea. Any keratometry reading of more than 47 diopters should be carefully looked at. In keratoconus, the keratometer mires are malformed and in severe cases, may not be apposed
- i) Topography - Any patient with topographic evidence of keratoconus with no clinical features is labelled as forme fruste keratoconus. Any island of steepening of inferior cornea should be suspected to have early or forme fruste keratoconus. Any patient with central cornea of more than 47D, difference in central cornea between the two eyes of more than 1D and difference between inferior and superior cornea at equidistant points of more than 1D should be suspected of keratoconus. Various indices including the Rabinowitz Index and Klyce Maeda Index are available to detect forme fruste keratoconus.⁶

In addition to steep cornea in keratoconus, asymmetrical bow tie pattern of astigmatism with skewed radial axis are important topographic features of keratoconus.

Ocular and systemic associations of keratoconus:

Though there a number of associations reported following are seen in practice more often:

Retinitis pigmentosa
Leber's optic atrophy

Ocular allergy including vernal Keratoconjunctivitis

Systemic associations:

Marfan's Syndrome
Ehler Danlos Syndrome

Acute Corneal Hydrops

This is corneal edema happening in a patient with keratoconus. This occurs as a consequence of rapid progression of keratoconus resulting in descemet's membrane tear. The cornea is swollen with result stromal edema and epithelial edema. Patient presents with rapid onset of loss of vision. Slit lamp examination will reveal tear in descemet's membrane which may be centrally located or may extend to the peripheral cornea. Stromal cleft may be visible.⁷ (Figure 4). Anterior segment OCT will help to visualize descemet's membrane tear in cases where it is not visible on slit lamp and also helps to find the dimensions of tear including the depth of the tear.

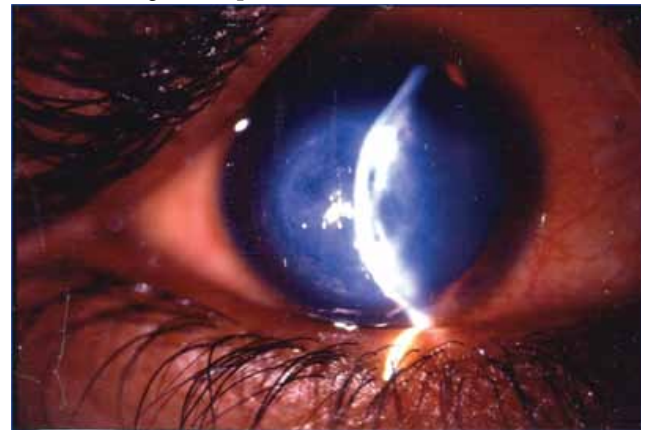

Figure 4. A case of acute corneal hydrops.

MANAGEMENT

For visual rehabilitation options are:

- 1) Glasses
- 2) Contact lenses
- 3) Intra Corneal rings
- 4) Deep lamellar anterior keratoplasty (DALK),
- 5) Large or eccentric penetrating keratoplasty
- 6) Large lamellar keratoplasty followed by penetrating keratoplasty
- 7) Implantable contact lens – Spherical and Toric

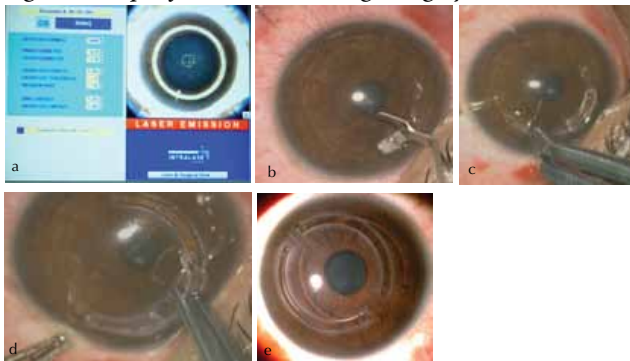
General measures. Avoid eye rubbing in allergy cases. Cold compression is suggested for relief of symptoms.

1. Spectacles regular or toric spectacles is useful in mild cases
2. Contact lens- In the initial stages soft contact lens may be of use. Rigid gas permeable (RGP) lenses are recommended contact lenses in keratoconus patients with mild to moderate astigmatism. These lenses give good quality vision and also have minimal dryness and inflammation in patients using lenses for many years. Specially designed lenses like Rose K lenses are also useful. Rose K lenses have additional blends helping the contact lenses to stay on the cornea even in severe

corneal coning . In severe ectasia, piggy back contact lens, where in a small RGP contact lens is applied over a large soft lens. Softperm lens have central RGP with a peripheral skirt of soft lens help in similar situation. Scleral lens RGP lenses can be used in large ectasia. Scleral RGP contact lenses are large contact lenses which sit on the sclera, so that even in severe ectasia the patient has be visually rehabilitated if the central cornea is clear.⁸

3. INTRACORNEAL RING SEGMENTS -Implantation of PMMA intracorneal rings into the paracentral cornea has been found successful to reduce the spherical and astigmatism error.⁹ These rings work on the principle of adding material on paracentral cornea to flatten the central cornea.¹⁰ Intacs or Ferrara are the common prototypes of intracorneal rings available. The central Cornea needs to be clear and the Cornea needs to be atleast 400 microns in thickness. The procedure involves making an incision with diamond knife, dissecting the grooves with a mechanical device or with a Femtosecond laser. The incision is sutured at the end of surgery. The steps of surgery are shown in Figure 5

Figure 5. Steps of Intracorneal Rings Surgery (INTACS)



a- Intrastromal channels being prepared with femtosecond laser at 70% depth

b- Channels being opened by Y spatula

c- Superior/larger intac being inserted

d- Inferior/smaller intac being inserted

e- Final outcome with intac being symmetrically placed

4. DEEP ANTERIOR LAMELLAR KERATOPLASTY (DALK)

Since endothelium is relatively healthy, DALK is becoming the surgery of choice for patients who are not having good vision with contact lens or are not able to tolerate contact lens for a long time or if the contact lens is popping out often.

In this procedure, the dissection is performed at the level of Descemet's membrane by injecting air bubble (viscoelastic) in front of Descemet's membrane. The tissue in front of the Descemet's membrane is carefully dissected (by a

combination of blunt and sharp) and removed. The donor cornea is transplanted after removing the endothelium. The steps are shown in table 6. DLAK can be performed even following hydrops with faint scar.

The advantages of DALK over full thickness penetrating keratoplasty include 1) we are leaving behind relatively healthy endothelium of patient 2) hence donor endothelium is not transplanted with less incidence of endothelium rejection and failure 3) Open eye situation with its disastrous consequences is avoided during surgery. ^{11, 12}

5. PENETRATINGKERATOPLASY (PK)-This is suggested in patients with dense central scar which is deeper and involving the descemet's membrane. The principle of surgery is to excise the cone in totality. Fleischer's ring on slit lamp shows base of the cone. Normally during transplantation graft of 0.5mm more is taken than the recipient bed. But in patients with Keratoconus same sized graft or a donor cornea 0.2mm more is preferred to reduce post-op myopia.¹³

If the cone is sagging, oval or extending to periphery, a large eccentric penetrating keratoplasty can be considered. In this situation, the graft host junction coming close to the limbus needs to be carefully watched for loose sutures. Intraocular pressure needs to be monitored closely

6. In patient with extensive limbus to limbus ectasia, a thin lamellar keratoplasty followed by a central PK may be done. If the thinning is limbus to limbus, performing lamellar keratoplasty may be technically very difficult. Removing the epithelium and putting a epikeratophakia kind of lenticule may be an alternate option.

7. Toric Implantable contact lens (ICL) is useful in patients with high myopia and astigmatism. This option may be considered if the Keratoconus is stable or is the progression is arrested by doing collagen cross-linking¹⁵ or the irregular astigmatism is reduced with improvement of visual acuity post implantation of intracorneal ring segments¹⁶. The central Cornea needs to be clear with no scarring. The natural lens should be clear. It is easy to implant the ICL as the anterior chamber is deep.¹⁴

COLLAGEN CROSS LINKING

In keratoconus there is change in the intrinsic biomechanical properties of the corneal collagen. Collagen cross linking uses photosensitizer Riboflavin and UVA 370 nm. The photosensitizer is activated into its triplet state generating reactive oxygen and to lesser degree superoxide anion radicals. The reactive oxygen can react further with various molecules including chemical covalent bonds thus bridging anion groups of collagen fibrils. The wavelength of

370nm has been chosen because it is the absorption peak of Riboflavin.¹⁷ The cross linking is formed maximum at the anterior 300 microns.¹⁸ Topographic guided PRK can be performed at the same sitting or at as later stage for residual refractive error correction.

Minimum of 400 microns corneal thickness is required for collagen cross linking using isotonic Riboflavin. If the thickness is low, endothelial toxicity may happen. If the corneal thickness is low, hypotonic Riboflavin is used till about 360 microns. Using hypotonic Riboflavin, cornea is swollen, corneal thickness measured and then the procedure is performed

The procedure is performed under topical anesthesia. The corneal epithelium is removed with a blunt spatula or multiple tiny incisions are made. The corneal is soaked with Riboflavin. A 0.1% Riboflavin solution (10 mg riboflavin-5-phosphate in 10 ml dextran 20% solution) is applied every 5 min starting 5 min before the irradiation. The irradiation is performed from a 1 cm distance for 30 min using a UVA double diode at 370 nm and an irradiance of 3mW/cm² (equal to a dose of 5.4J/cm²). The required irradiance is controlled in each patient directly before the treatment to avoid a potentially dangerous UVA overdose. In regular procedure, 30 minutes of Riboflavin soaking and 30 minutes of UV exposure is done. In accelerated Riboflavin procedure using Avedro machine, the soaking time is 20 minutes with UV exposure of 4 minutes.¹⁹

CORNEAL HYDROPS

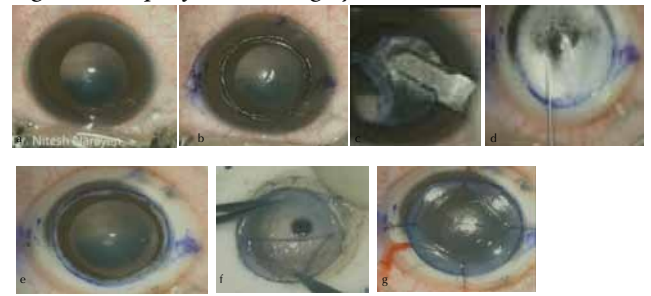
This is a rare complication of keratoconus and other ectatic disorder including pellucid marginal corneal degeneration (PMCD) and keratoglobus. In this condition, the descemet's membrane ruptures causing stromal edema and diminution of vision. Early onset of keratoconus and eye rubbing seems to predispose individuals to develop corneal hydrops.²

MANAGEMENT

Cycloplegic and antibiotic ointment at bed time, intra cameral injection of air, SF₆ or C₃F₈ gas has found to enhance the resolution of hydrops.²⁰ Following resolution of corneal hydrops central cornea gets flattened and it may become possible to fit contact lens. In case there is significant central and dense corneal opacity corneal transplant may be required.

DALK can also be performed in cases of resolved hydrops with good visual re-sults.^{21,22} (Figures 6,7)

Figure 6. Steps of DALK surgery.



- a- Advanced Keratoconus
- b- Partial trephination
- c- Anterior stroma being removed which would facilitate in deeper injection of air for the big bubble
- d- Big bubble being achieved with bent 26G needle
- e- Bare DM after removal of the stroma
- f- DM being stripped from the donor cornea
- g- Donor sutured on the recipient bed with intermittent 10-0 nylon sutures

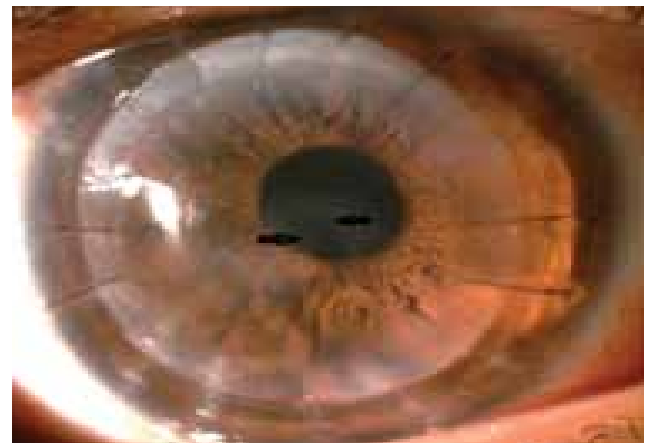


Figure 7. Clinical picture following DALK surgery for resolved hydrops.

DIFFERENTIAL DIAGNOSIS OF KERATOCONUS

1. Pellucid Marginal Corneal Degeneration-There is an inferior band of narrow thinning and ectasia of the normal cornea above it (Figure 8).



Figure 8. Clinical picture of PMCD. Note the inferior band of thinning with ectasia of normal cornea above the thinned area.

2. Though PMCD is normally seen inferiorly it is also seen in nasal and temporal cornea. On topography there is characteristic red band of steepening which goes across the nasal and temporal hemimeridians to form a loop cylinder; against the rule astigmatism with inferior loop

cylinder is seen in PMCD. When the topography rings does not reach the entire cornea a butterfly pattern is seen.

3. Keratoglobus- There is limbus to limbus thinning and protrusion of the entire cornea.
3. Posterior keratoconus- In this situation, the anterior surface of cornea is normal. Ectasia of only posterior cornea is seen.

REFERENCES:

1. Rabinowitz YS. The genetics of keratoconus. *Ophthalmol Clin North Am.* 2003 ;16:607-20
2. Rabinowitz. *Keratoconus Surv Ophthalmol* 1998 ;42:297-319
3. Sharma N, Rao K, Maharana PK, Vajpayee RB. Ocular allergy and keratoconus. *Indian J Ophthalmol* 2013 ;61:407-9
4. Cingu AK, Cinar Y, Turkcu FM, Sahin A, Ari S, Yuksel H, Sahin M, Caca I. Effects of vernal and allergic conjunctivitis on severity of keratoconus. *Int J Ophthalmol* 2013 ;6:370-4
5. Fong AH, Shum J, Ng AL, Li KK, McGhee S, Wong D. Prevalence of ocular abnormalities in adults with Down syndrome in Hong Kong. *Br J Ophthalmol.* 2013 ;97:423-8
6. Ortiz-Toquero S, Rodriguez G, de Juan V, Martin R. Repeatability of Placido-Based Corneal Topography in Keratoconus. *Optom Vis Sci.* 2014 Oct 23
7. McMonnies. Mechanisms for acute corneal hydrops and perforation. *Eye Contact Lens* 2014 ;40:257-64
8. Rathi VM, Mandathara PS, Dumpati S. Contact lens in keratoconus. *Indian J Ophthalmol.* 2013 ;61:410-5
9. Rabinowitz YS. Intacs for keratoconus. *Curr Opin Ophthalmol* 2007 ;18:279-83
10. Rabinowitz YS. INTACS for Keratoconus. *Int Ophthalmol Clin* 2010 ;50:63-76.
11. Romano V, Iovieno A, Parente G, Soldani AM, Fontana L. Long-Term Clinical Outcomes of Deep Anterior Lamellar Keratoplasty in Patients With Keratoconus. *Am J Ophthalmol.* 2014 Dec 6.
12. Maharana PK, Agarwal K, Jhanji V, Vajpayee RB. Deep anterior lamellar keratoplasty for keratoconus: a review. *Eye Contact Lens.* 2014 ;40:382-9
13. Choi JA, Lee MA, Kim MS. Long-term outcomes of penetrating keratoplasty in keratoconus: analysis of the factors associated with final visual acuities. *Int J Ophthalmol.* 2014;18:517-21
14. Kummelil MK, Hemamalini MS, Bhagali R, Sargod K, Nagappa S, Shetty R, Shetty BK. Toric implantable collamer lens for keratoconus. *Indian J Ophthalmol.* 2013 ;61:456-60
15. Shafik Shaheen M, El-Kateb M, El-Samadouny MA, Zaghoul H. Evaluation of a toric implantable collamer lens after corneal collagen crosslinking in treatment of early-stage keratoconus: 3-year follow-up. *Cornea* 2014 ;33:475-80
16. Dirani A, Fadlallah A, Khoueir Z, Antoun J, Cherfan G, Jarade E. Visian toric ICL implantation after intracorneal ring segments implantation and corneal collagen crosslinking in keratoconus. *Eur J Ophthalmol.* 2014 ;24:338-44
17. Raiskup F, Theuring A, Pillunat LE, Spoerl E. Corneal collagen crosslinking with riboflavin and ultraviolet-A light in progressive keratoconus: Ten-year results. *J Cataract Refract Surg* 2015 ;41:41-6.
18. Brittingham S, Tappeiner C, Frueh BE. Corneal cross-linking in keratoconus using the standard and rapid treatment protocol: differences in demarcation line and 12-month outcomes. *Invest Ophthalmol Vis Sci* 2014 2;55:8371-6.
19. Konstantopoulos A, Mehta JS. Conventional Versus Accelerated Collagen Cross-Linking for Keratoconus. *Eye Contact Lens* 2014 Dec 10
20. Shah SG, Sridhar MS, Sangwan VS. Acute corneal hydrops treated by intracameral injection of perfluoropropane (C3F8) gas. *Am J Ophthalmol* 2005 ;139:368-70.
21. Nanavaty MA, Daya SM. Outcomes of deep anterior lamellar keratoplasty in keratoconic eyes with previous hydrops. *Br J Ophthalmol.* 2012 ;96:1304-9
22. Narayan N, Sridhar MS. Perfluoropropane (C3F8) gas injection followed by deep anterior lamellar keratoplasty (DALK) in severe keratoconus. *Eye* 2014 ;28:1260-1

Correspondence:



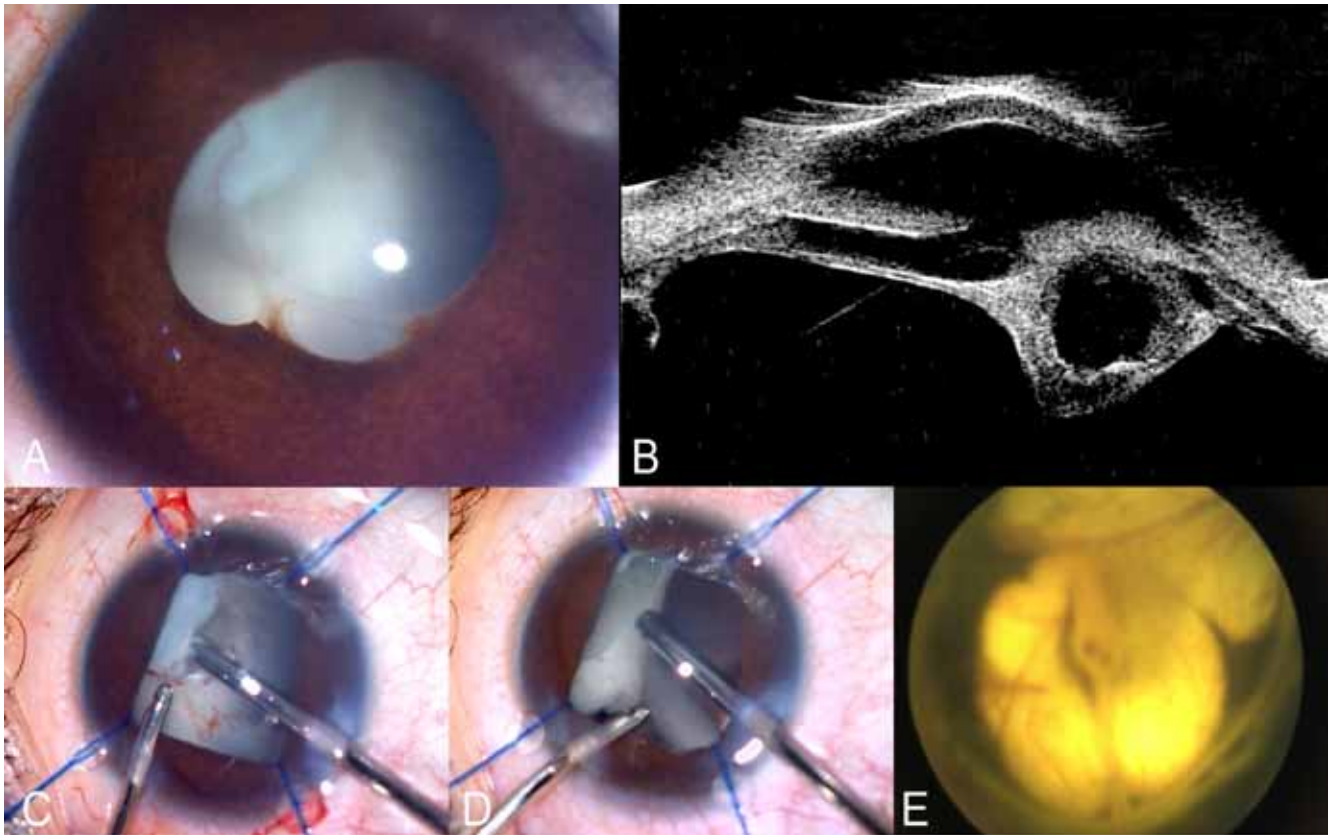
Dr Nitesh Narayen MS
Maxivision Eye Hospital
Hyderabad
Email: drniteshnarayan@gmail.com



Dr M.S. Sridhar MD
KIMS Hospital, Secunderabad
Email: sri.vision@yahoo.co.in
www.doctormssridhar.com

Persistent fetal vasculature (PFV) with unusual finding of lenticular cyst

Dr Anjali Chandrashekar; Dr Ramesh Kekunnaya



PFV is the second most common cause of unilateral acquired cataract of infancy after posterior lenticonus .1 It can also present at birth as a congenital cataract. It has peculiar clinical and ultrasonography findings which help differentiate it from other causes of leucocoria.

Typical findings of anterior PFV on ultrasound include elongated ciliary process, swollen lens, thickened anterior hyaloid phase causing double linear echoes.² Surgical management of an anterior PFV associated cataract can be done via limbal and pars plana route. Lens aspiration is performed with irrigation and aspiration cannula or more commonly a mechanized vitrectome with the help of microscissors and capsulorhexis forceps for removing lens plaques. Careful attention to intraoperative hemostasis is mandated in these cases. We report a case with an unusual lenticular morphology confirmed with Ultrasound Biomicroscopy which has not been previously reported.

A 6 months old infant presented with Lenticular opacity with prominent intralenticular vasculature (A). Ultrasound Biomicroscopy revealed elongated ciliary process with temporally decentered lens echoes and intralenticular cystic space suggestive of lenticular cyst (B). Biometry revealed an axial length of 21.52mm and 25.94mm in right and left eye respectively. Lens aspiration via limbal route was performed (C,D). A retro-lenticular stalk was noted suggestive of persistent fetal vasculature. Peroperative fundus examination revealed posterior staphyloma as the cause for axial myopia (E).

REFERENCES:

1. Pollard ZF. Persistent hyperplastic primary vitreous: diagnosis, treatment and results. *Trans Am Ophthalmol Soc.* 1997;95:487-549.
2. Mackeen LD, Nischal KK, Lam WC, Levin AV. High-frequency ultrasonography findings in persistent hyperplastic primary vitreous. *J AAPOS.* 2000 Aug;4(4):217-24.

Correspondence:



Dr Anjali Chandrashekar

LV Prasad Eye Institute,
Banjara Hills, Hyderabad
Email: anjalic_s@yahoo.co.in



Dr Ramesh Kekunnaya

LV Prasad Eye Institute
Banjara Hills, Hyderabad
Email: rameshk@lvpei.org

Chronic Progressive External Ophthalmoplegia: A Case Report

Dr Sree Kumar Vaggu; Dr Sowjanya Thorikonda

INTRODUCTION:

CPEO is a clinical syndrome characterised by slowly progressive paralysis of extraocular muscles. It is a common presenting sign of a potential multisystem disorder. Ptosis and extraocular immobility are the common ocular manifestations. We report a 35 year old male patient with CPEO.

CASE REPORT:

We present a case of a 35 year old male patient who came to our Out Patient Department on 9-12-2014, with chief complaints of bilateral ptosis and restricted eye ball movements.

HISTORY:

Ptosis was insidious in onset and slowly progressive over 15 years. It was associated with restriction of eye movements in all directions, and with watering of the eyes, pain & photophobia of right eye. There was no diurnal variation. No history of trauma or head injury, usage of any medications. No history of any syncopal attack. No History of diplopia He also complained about dysphagia for 10 years. There was skin involvement with dermatitis of scalp, loss of hair on temporal aspects, loss of eyebrows and eye lashes.

There was no significant family history pertaining to the disease.

No significant personal history was relevant pertaining to the disease.

EXAMINATION:

Eyebrows were elevated with absence of upper eyelid crease. Chin position was elevated with frontalis overaction. Bilateral ptosis with palpable fissure height of 4mm was present with poor levator function (Figure 1).

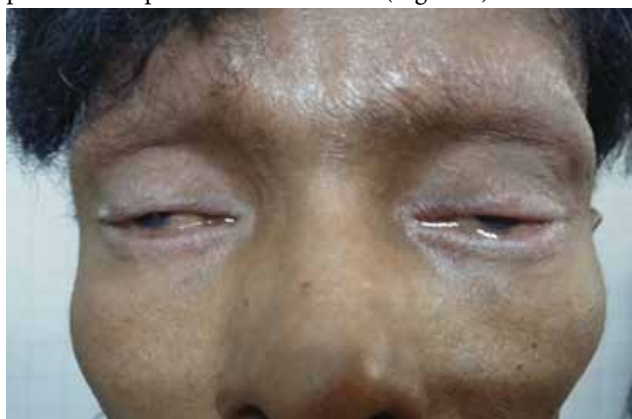

Figure 1: Extra ocular movements were absent in all directions. Bells Phenomenon was absent.

Marcus Gunn jaw winking phenomenon was absent.

Visual acuity in Right eye was 6/60, Left eye 6/24.

Exposure Keratitis was present in lower half of cornea in both eyes.

Fundus examination revealed normal fundus.

General examination: The patient was thin built, with generalized wasting of all muscles (Figure 2).

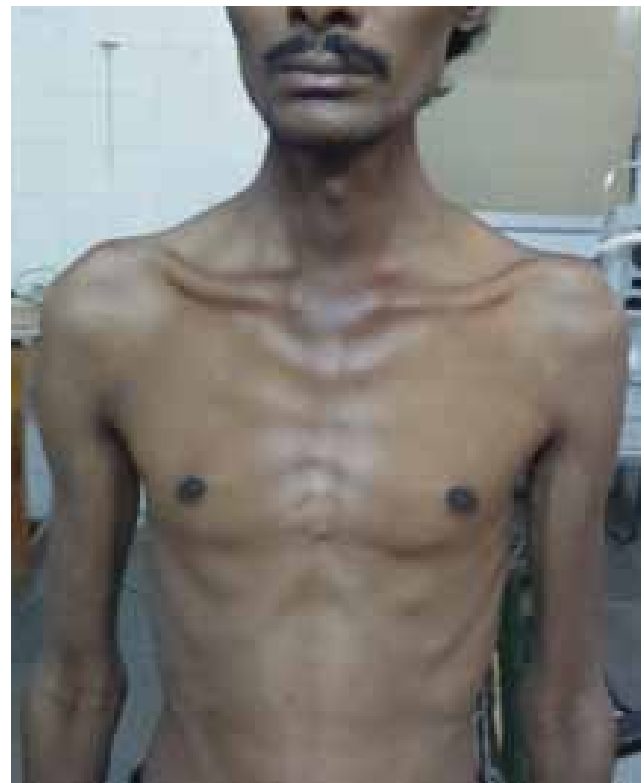

Figure 2.

INVESTIGATIONS:

Serum Creatinine Phosphokinase was raised to 354IU/L (Ref range 20-200)

Serum Lactate was slightly elevated to 2.9mmol/l (Ref range 0.50-2.22)

Serum Pyruvate is also elevated to 1.43mg/dl (Ref range 0.37-0.88)

Thyroid Profile was within normal range.

MRI Brain and Extraocular muscles both sides was normal.

ECG and 2D ECHO was within normal limits.

EMG Findings were suggestive of Primary Muscle disease.

Muscle Biopsy of lateral quadriceps showed granular fibres.

MGT showed red ragged fibres and SDH showed blue ragged fibres. COX shows COX negative fibres, highlighted on COX-SDH giving an impression of Mitochondrial Myopathy (CPEO) plus.

Molecular Genetic Report – A total of 31 variations were

observed in Mitochondrial DNA of the patient and all of them were found to be polymorphic and silent mutations. No pathogenic mutations were observed in Mitochondrial DNA. However multiple deletions of mitochondrial DNA were observed which may be the cause for the disease.

DISCUSSION:

Compared to the approximately 30,000 genes in nuclear DNA, human mitochondrial DNA genome has only 16,568 bp and codes for only 37 genes. Nevertheless, defects in mitochondrial genome can account for a range of mitochondrial diseases including CPEO, Kearns-Sayre syndrome, Lebers Hereditary Optic Neuropathy, mitochondrial encephalopathy, Lactic acidosis, and stroke-like episodes (MELAs), Myoclonus epilepsy and ragged red fibres (MERRF).

The most common mitochondrial disorder to affect muscle is CPEO. Causes are single mitochondrial DNA deletions, mitochondrial DNA point mutations A3243G (most common).

The CPEO syndrome designates a group of clinical findings characterised by slowly progressive bilateral ocular immobility. Ptosis and orbicularis oculi weakness are frequently prominent. Indeed ptosis usually precedes the mobility disturbance. Slowed saccades are the earliest dysfunctions of ocular mobility dysfunction. Onset is typically insidious and can occur any time from infancy to old age. The process is typically symmetric and patients typically tend not to complain of diplopia. Eventually eyes may become unresponsive even to caloric stimulation. In long standing CPEO, forced ductions can be positive presumably due to fibrosis of the extraocular muscles. Pupils and ciliary muscle are always spared and disturbances of sensation are absent. Down gaze is usually well preserved until late in the disease.

Systemic involvement in CPEO includes facial and limb muscle (60%-90%), endocrine (67%), cardiac conduction disorder (26%), ataxia and tremor (39%), polyneuropathy (23%), dementia and other CNS abnormalities (13%), and vestibular dysfunction /hearing loss.

Some of the more common neurological findings are facial, bulbar, limb myopathies, deafness, ataxia, spasticity, peripheral neuropathy, gastro intestinal myopathy and neuropathy and vestibular dysfunction, dementia, episodic encephalopathy or coma. Elevated CSF protein, calcification of the basal ganglion and spongiform changes in the brainstem.

Associated ophthalmic features include optic atrophy, corneal opacities, corneal oedema and cataracts. Systemic manifestations may involve the cardiac, endocrine, skin or skeletal system including cardiac conduction defects, short stature, diabetes mellitus, delayed sexual maturation, hypogonadism, hypomagnesemia, hypoparathyroidism, hypothyroidism, and respiratory insufficiency.

CONCLUSION:

Thus this is a case of progressive bilateral ptosis and ocular immobility with generalised weakness of skeletal muscles, dysphagia, skin involvement, with raised creatinine phosphokinase, serum lactate and serum pyruvate. Muscle biopsy revealed red ragged fibres and genetic analysis showed a total of 31 variations in mitochondrial DNA which were polymorphic and silent mutations and multiple deletions of mitochondrial DNA giving an impression of mitochondrial myopathy (CPEO) plus. The patient is presently on treatment with coenzyme Q10.

Correspondence:



Dr Sree Kumar Vaggu

Department of ophthalmology

Regional Eye Hospital

Kakatiya Medical College, Warangal, Telangana.

Email: vaggusreekumar@gmail.com

Clinical Profile of Ocular Surface Squamous Neoplasia: A Retrospective Case Series.

Dr Sree Kumar Vaggu ; Dr Jeevitha Gaddala

Introduction

Ocular surface squamous neoplasia (OSSN) is a spectrum of dysplastic lesions of cornea and conjunctiva ranging from simple dysplasia to carcinoma in-situ [conjunctival - corneal intra epithelial neoplasia (CCIN)] to invasive squamous cell carcinoma (SCC) [1]. Incidence of OSSN ranges from 0.02-3.5 per 1,00,000 population and varies geographically with greater frequency near equator [2]. OSSN predominantly occurs in elderly males with an average age of 56 years [1]. It has predilection for corneo-scleral limbus reinforcing the theory that transition zone is at increased susceptibility for dysplastic changes [3]. Lack of awareness, misinterpretation of OSSN as benign conditions like keratoconjunctivitis, pterygium, papilloma, limbal dermoid, or foreign body granuloma and slow growth of lesion in relatively asymptomatic patient, may mislead the clinician into false sense of security with resultant recurrence and metastasis. This is a retrospective case report of 3 patients who underwent surgical excision for histopathologically proven cases of ocular surface squamous neoplasia (OSSN) at Regional Eye Hospital, Warangal.

CASE REPORT 1

- 35 years old female patient presented with whitish mass at right temporal conjunctiva associated with watering and foreign body sensation for last 2 months. Initially mass was small in size but gradually increased to present size of 5 mm in diameter (Figure 1).
- On slit lamp biomicroscopy, a whitish pink, raised, fixed nodular fungating mass of 5 mm diameter was noted at the temporal periphery of cornea of right eye.
- The lesion involved the superficial layer of conjunctiva without any visible extension to adjacent ocular tissue. Conjunctival congestion was noted adjacent to the lesion. Feeder vessel seen. Left eye was normal. There was no lymphadenopathy and systemic examination was within normal limits.
- After excision biopsy confirmed as well-defined squamous cell carcinoma (Figure 2).
- This is rare for a female at this age and hence we should look for immune status and history of any immunosuppressive drug use.

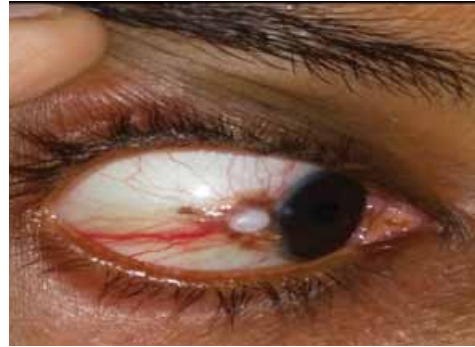

Figure 1: Conjunctival lesion showing feeder vessel.

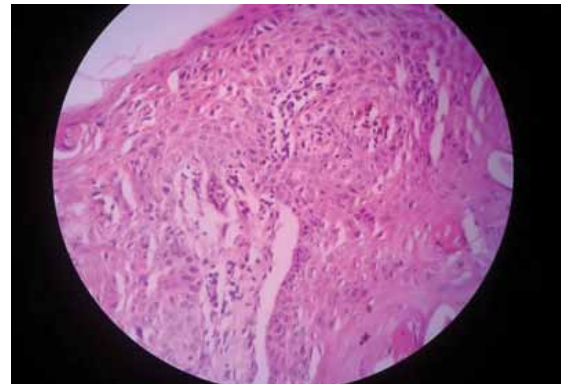


Figure 2: H&E stained sections showing stratified squamous epithelium; cells are polygonal showing increased n/c ratio, hyperchromatism, polymorphism and prominent nucleoli. Plenty of mitotic figures seen.

CASE REPORT 2:

- A 45 year old female pt came with complaints of foreign body sensation and watering for 3 months.
- On examination a raised lesion of 5 x 4 mm was at nasal corneo-scleral junction with irregular borders and surface, with feeder vessels seen (Figure 3).
- The lesion involved the superficial layer of conjunctiva without any visible extension to adjacent ocular tissue.
- No lymphadenopathy, systemic examination was within normal limits.
- Other eye was normal.
- Diagnosed as degeneration of pterygium; on excision biopsy was confirmed as well defined squamous carcinoma (Figure 4).
- Hence every lesion at limbal junction should be subjected to histopathological examination which effectively rules out misinterpretation and defines postoperative management.

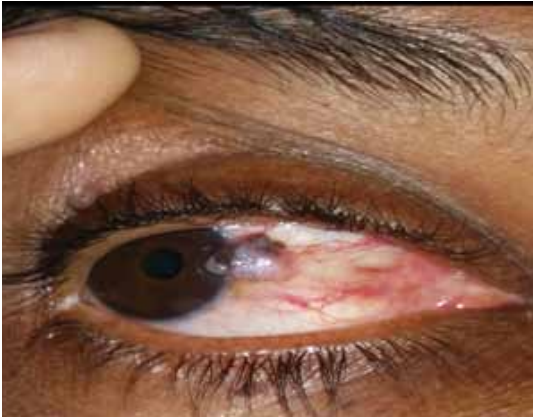

Figure 3. Conjunctival lesion showing degeneration.

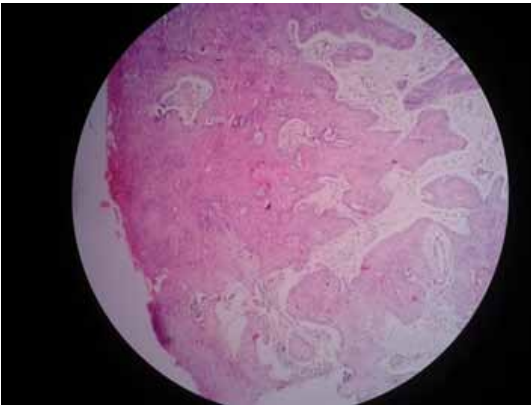


Figure 4. Thickened atypical stratified squamous epithelium showing invasion (islands).

CASE REPORT 3:

- A 65 year old diabetic lady presented with complaints of recurrence of lesion on nasal side of right eye after she underwent excision 5 years back.
- Associated with watering, photophobia, restriction of ocular movements
- On examination there was a recurrent pterygium extending upto 4mm onto cornea (Figure 5).
- Excision biopsy was done and sent for histopathology evaluation.
- Confirmed as well-defined squamous carcinoma (Figure 6).
- Every recurrent pterygium should be subjected for histopathology especially in an elderly patient.

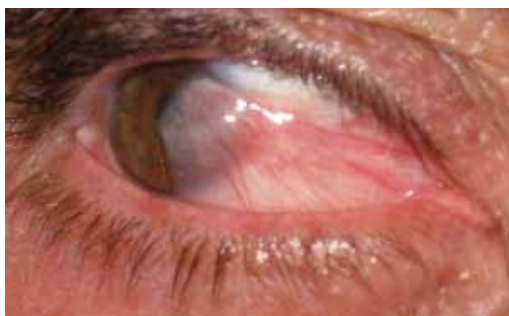

Figure 5. Recurrence after pterygium excision).

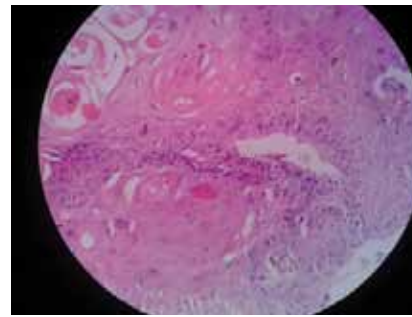


Figure 6. Squamous epithelium showing individual cell keratinisation, high n/c ratio, hyperchromatism, prominent nucleoli. Areas with keratin pearls are also seen.

Discussion: OSSN includes precancerous and cancerous lesions of conjunctiva and cornea. Conjunctival/corneal intraepithelial neoplasia refers to dysplasia involving less than full thickness of epithelium and carcinoma in situ (CIS) refers to full thickness changes [9]. SCC of cornea breaks through epithelial basement membrane into Bowman's layer and stroma. OSSN has predilection for corneo-scleral limbus as it is transition zone with greatest mitotic activity. Isolated SCC of cornea may occur due to centripetal movement of abnormal epithelial cells from limbus which becomes neoplastic after migration [10].

Although advanced malignant lesions frequently exhibit clearly invasive features, in-situ or superficially invasive lesions typically resemble their benign counterparts quite closely and are difficult to identify clinically. These lesions are often misdiagnosed for a variety of benign lesions and though removed, are not usually subjected to histopathological examination. Recurrence rates are naturally high in such cases (5-50%) which are mainly related to the inadequacy of resection margins at initial excision [11]. The criteria of differentiation between CIN III/ CIS and invasive carcinoma are cellular pleomorphism, hyperkeratinised cells, large number of inflammatory cells and tumour diathesis in the background [11].

CONCLUSION: Many ocular surface lesions though removed are not submitted for histopathological examination causing complications and metastasis. Every ocular lesion should be submitted for histopathological examination which helps the surgeon in decision making and definitive postoperative management of OSSN.

Correspondence:



Dr Sree Kumar Vaggu

Department of ophthalmology
Regional Eye Hospital
Kakatiya Medical College, Warangal,
Telangana.

Email: vaggusreekumar@gmail.com

Intraocular Cysticercosis - A Differential Diagnosis For Leucocoria

Dr P Neha Sudhakar; Dr Kishore Kumar; Dr DV Giddaiah

ABSTRACT

Cysticercosis is a systemic parasitic disease caused by the larval form of cestode *Taenia solium*. It has a worldwide distribution and is potentially harmful with variable clinical manifestations. The most commonly involved sites include eye, brain, bladder wall, and

heart. Ocular cysticercosis can be extraocular or intraocular and may present with varied clinical symptoms. We report the condition in a 10 year old female child who presented with redness and painful diminution of vision in right eye for 5 days where cysticercus cyst was found within the vitreous. Multiple sites of involvement was noted including the central nervous system, lungs and spleen. This case is reported to highlight the prime importance of systemic evaluation of a patient of ocular cysticercosis, and the young age of the patient.

INTRODUCTION

Cysticercosis is one of the most serious parasitic infestations found almost all over the world, and listed as one of the neglected tropical diseases (NTDs)^{1,2}. Cysticercosis is the infestation by *Cysticercus cellulosae*, the larval form of the pork tapeworm, *Taenia solium*. It is contracted by (a) ingestion of the infective cysticerci in under cooked pork; (b) Ingestion of eggs of *T. solium* in contaminated water, food or vegetables; and (c) Regurgitation of eggs from the small intestine^{3,4}.

Ocular cysticercosis may be extraocular (in the orbital tissue or subconjunctival) or intraocular (in the vitreous, subretinal space or anterior chamber)⁵. Ocular cysticercosis is common in the Indian subcontinent.⁶ It is also common in South and Central America, Mexico, the Philippines, Eastern Europe, Southeast Asia and Russia^{7,8}.

CASE REPORT

A ten year old female non-vegetarian presented with painful diminution of vision and redness in right eye for 5 days. There was no history of fever, convulsions, bowel and bladder disturbances, pork intake, contact with pets.

Visual Acuity was RE No PL and LE 20/20. Patient was orthophoric and ocular motility was full and painless in both the eyes.

On slit lamp examination, right eye had circumciliary congestion with flare 2+ with cells trace and pigment dispersion over anterior capsule of lens. Pupillary reaction was sluggish. There was marked vitreous inflammation with no view of the posterior pole (Figure 1). Left eye evaluation was unremarkable.

B-scan of right eye posterior segment revealed a mobile intraocular mass with sonolucent area with echodense center with well-defined margins suggestive of hanging drop sign (Figure 2). Moderate to low reflective vitreous echoes were noted around the mass. Choroidal thickening and optic disc oedema were noted. A-scan showed high amplitude spikes corresponding to cyst walls and scolex. B-scan orbit revealed no soft tissue or extraocular muscle involvement.

The neurological and general physical examination revealed no abnormalities.

Complete blood count with differential leucocyte count and ESR were normal. Montoux test showed induration of 22 mm which is significant.

Chest X ray PA view revealed small nodular opacity with irregular shape in right midzone region suggestive of soft tissue calcification or calcified nodule (Figure 3). Respiratory system examination revealed no abnormality and patient was placed on observation.

CT scan brain revealed multiple calcified granulomas with diameter ranging from 2 -7 mm in bilateral cerebral and cerebellar hemispheres, left basal ganglia and thalamus (starry sky pattern) without perilesional oedema (Figure 4). CT Orbit revealed mild iso-hyperdense heterogenous attenuation in right globe; no involvement of extraocular muscles and lids.

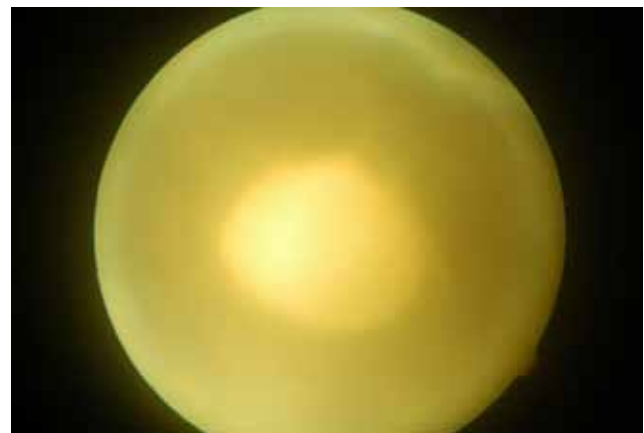


Figure 1. Fundus picture showing cyst in vitreous

Ultrasound Abdomen revealed multiple splenic calcifications.

Enzyme linked immunosorbent assay for serum antibodies

against cysticercosis was positive.

Stool examination was negative for parasites.

Depending on the above findings a diagnosis of multiple organ involvement was made.

Neurophysician opinion was taken and patient was put on oral Albendazole 400 mg daily in divided doses and oral corticosteroids 50 mg daily for 4 weeks. Patient was followed up on weekly basis and clinical improvement was noted. Patient is scheduled for vitreoretinal surgery for removal of cyst after inflammation has come down.

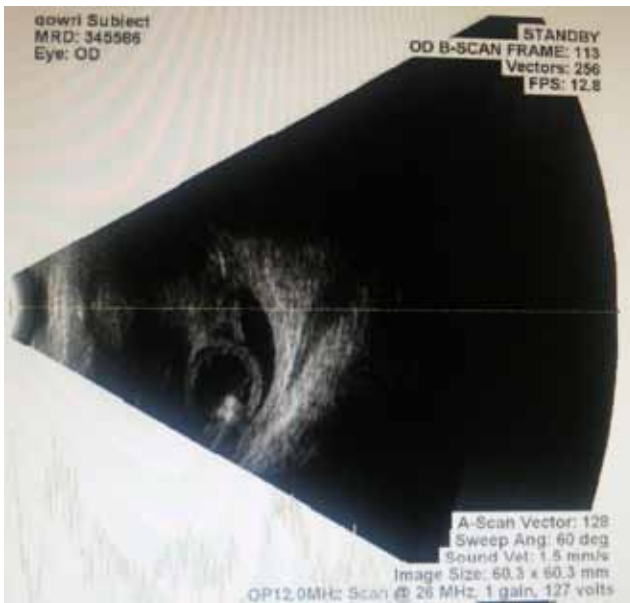


Figure 2. B- scan showing hanging drop sign

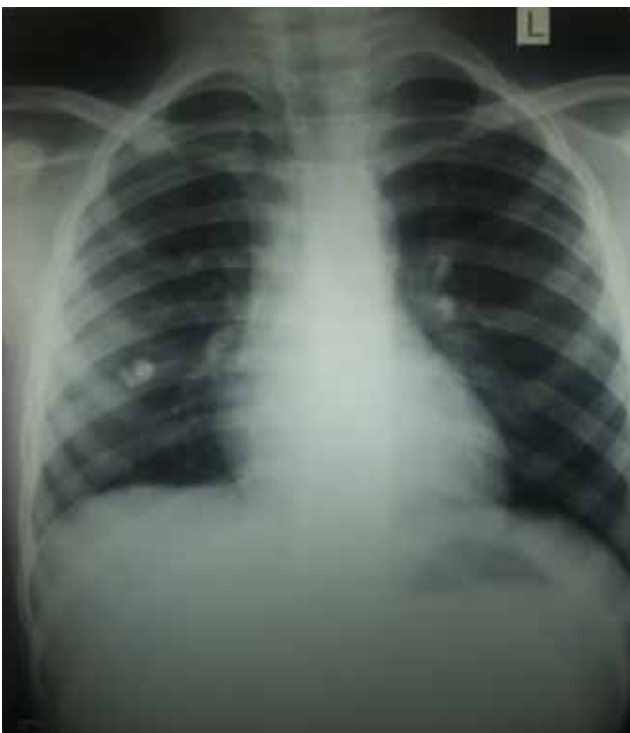

Figure 3. Chest X RAY with soft tissue nodule

DISCUSSION

Ocular involvement with *cysticercus cellulosae* is well known. Sommering⁵ first reported a case of ocular cysticercosis in 1980. The posterior segment is more commonly affected in Western countries, whereas in India, the cysts are more often found extraocularly.¹⁴ Once considered as an endemic disease in developing countries, there has been a gradual change in the sociodemographic trends of ocular cysticercosis due to improved hygiene and public awareness¹⁰.

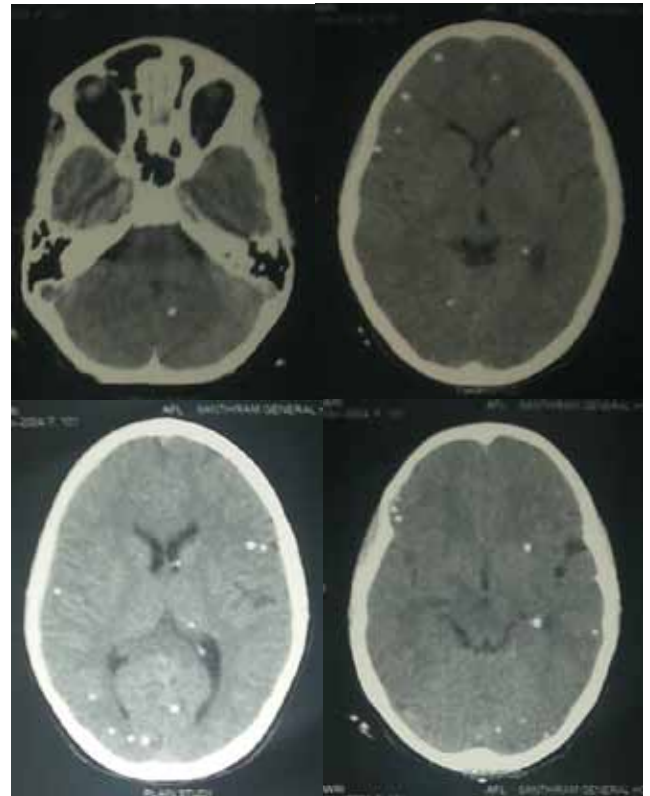


Figure 4. CT Brain shows lesions in cerebral and cerebellar hemispheres, thalamus and left basal ganglia

Neurocysticercosis is the most frequent systemic manifestation. It is the cause of epilepsy in up to 50% of Indian patients presenting with partial seizure¹⁵. Intraocular cysticercosis usually presents with reduction of vision, and signs of ocular inflammation. It is believed that the larva reaches the sub retinal space through posterior ciliary arteries. As the cyst develops, it may cause exudative retinal detachment. Perforation of retina results in a free-floating intravitreal cyst.⁹⁻¹¹ Cysticerci can lodge themselves in any part of the ocular and orbital tissue and can lead to a diverse spectrum of clinical presentations. Of the diagnostic imaging modalities employed, ultrasonography was found to be better than CT scan for detection of scolex. CT scan (head) is mandatory for all patients to rule out associated neurocysticercosis.

Therapy must be individualized according to the location of the parasite and tailored depending on the activity of the

disease. A combination of oral albendazole and steroid is quite effective. Intraocular cyst requires timely surgical removal to obviate sight threatening sequelae⁹. Intravitreal or sub retinal cysticercus without surgical removal of the larva usually leads to blindness within 3–5 years.¹³ An unusual feature of our patient was that she presented as leucocoria with ocular inflammatory signs, and an ultrasonographic appearance of calcification. This clinical presentation in a child strongly points towards the diagnosis of necrotic retinoblastoma¹².

Although rare, intraocular cysticercosis could present as leucocoria and pose a diagnostic problem in children. It should be considered in the differential diagnosis of leucocoria presenting with ocular inflammation, especially in endemic areas.

As it is disease of multiorgan involvement, thorough systemic work up is of prime importance.

REFERENCES

1. Budke CM1, White Jr AC, Garcia HH. Zoonotic larval cestode infections: neglected tropical diseases *PLoS Negl Trop Dis* 2009; 3:e319
2. Flisser A, Craig PS, Ito A. Cysticercosis and taeniosis: *Taeniasolium*, *Taeniasaginata* and *Taeniaasiatica*. In: Palmer SR, SoulsbyLPR, Torgerson PR, Brown DWG, editors. *Oxford textbook of zoonoses*. Oxford: Oxford University Press; 2011. p. 625–42.
3. Daniel Albert, Frederick Jakobiec, Nancy Robinson *Principles & Practice of Ophthalmology*, W.B. Saunders Co, copyright 1994;462,1711–1751,2308,2319,3073.
4. SJ Ryan. *Ocular Cysticercosis Retina*. 2nd ed. vol. 2. St. Louis (USA): CV Mosby and Co; 1994.
5. Duke-Elder S, Perkins ES. Diseases of the uveal tract. In: DukeElder S (Ed). *System of Ophthalmology*, Vol. 9. St. Louis: CV Mosby; 1966. p. 478.
6. Malik SRK, Gupta AK, Chowdhary S. Ocular Cysticercosis. *Am J Ophthalmol* 1986; 66:1168–71.
7. King CH. Cestodes (Tapeworms). In: Mandell G, Bennett JE, Dolin R (Eds). *Principles and Practice of Infectious Diseases*, Vol. 2. New York: Churchill-Livingstone; 1995. p. 2544.
8. Veliath AJ ,Ratnakar C, Thakur LC, Cysticercosis in South India. *J Trop Med Hyg* 195;88:25-9)
9. Kruger-Leite E, Jalkh AE, Quiroz H et al. Intraocular cysticercosis. *Am J Ophthalmol* 1985; 99: 252–257
10. Atul K, Kumar H, Mallika G, Sandip M. Socio-demographic trends in ocular cysticercosis. *Acta Ophthalmol Scand* 1995;73: 438–441.
11. Topilow HW, Yimoyines DJ, Freeman HM et al. Bilateral multifocal intraocular cysticercosis. *Ophthalmology* 1981; 88:1166–1172.
12. Shields JA, Shields CL, Eagle RC et al. Calcified intraocular abscess simulating retinoblastoma. *Am J Ophthalmol* 1992;114: 227–229.
13. Sen DK, Mohan H. Ocular cysticercosis in India. *J Pediatr Ophthalmol Strabismus*. 1978;15:96-102.
14. Chowdhary A, Bansal R, Singh K, et al. Ocular cysticercosis—a profile. *Trop Doct*. 2003;33:185-8.
15. Rajshekhar V, Joshi DD, Doanh NQ, et al. *Taeniasolium* taeniosis/ cysticercosis in Asia: epidemiology, impact and issues. *Acta Trop*. 2003;87(1):53-60.

Correspondence:



Dr P Neha Sudhakar

Santhiram Medical College and

General Hospital, Nandyal

Email: nehaperaka7@yahoo.com

Perfluorocarbon Liquid as short-term tamponade for posterior giant retinal tear

Dr Jay Chabalani, MS

An 11 year-old female presented with sudden vision loss in the left eye following blunt trauma. On examination, her best corrected visual acuity (BCVA) was perception of light only with projection inaccurate. Anterior segment examination of the left eye showed subluxated lens. On fundus examination media was hazy due to vitreous haemorrhage. Giant retinal tear was noted posterior to equator with subretinal haemorrhage at macula (Figure 1). Retinal detachment was noted anterior to tear. Ultrasonography confirmed the findings.

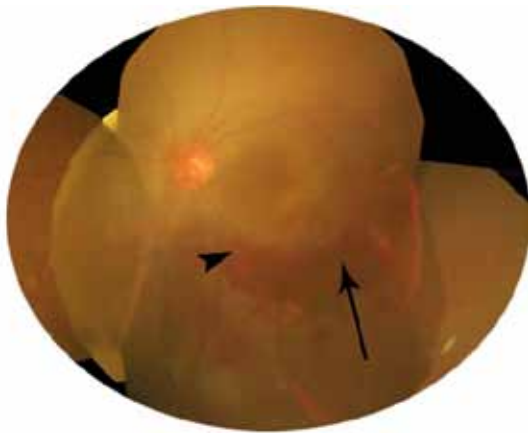


Figure 1 – Montage fundus image showing hazy media with large posterior giant retinal tear (arrow) with subretinal hemorrhage (arrow head).

Patient underwent pars plana lensectomy and vitrectomy. Intra-operatively large amount of subretinal blood was noted under the macula. Perfluorocarbon liquids (PFCL)-Fluid exchange was done. Retina was attached through out. Endolaser photocoagulation performed around the tear. Patient was kept in strict supine position and underwent PFCL/Silicone oil exchange after 5 days of the first surgery. Postoperative period was uneventful. At four months of follow up her BCVA was 20/60 in the left eye with attached retina and subretinal fibrosis but spared macula (Figure 2).

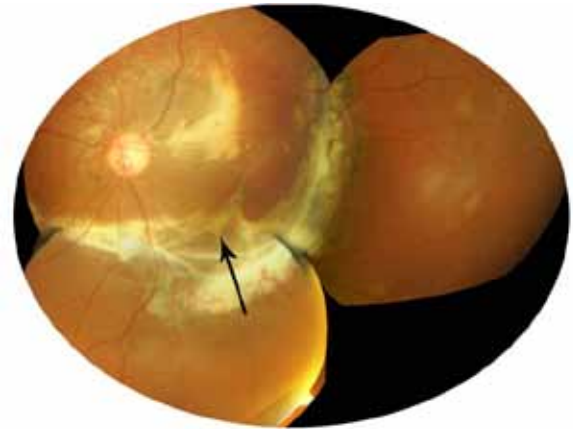


Figure 2 - Montage fundus image showing attached retina with subretinal fibrosis with spared fovea.

The patient underwent silicone oil removal at 4 months of follow up. Patient was on regular follow up and maintaining BCVA of 20/60 at one year of follow up.

PFCL have been used as an intra-operative tool and short term postoperative tamponade for a mean of 5 days to 16.5 days.[1,2] Ocular toxicity due to retained PFCL including uncontrolled intraocular pressure, corneal epithelial toxicity, and decreased focal sensitivity of the retina[3] have been reported. In vitro study showed that PFCL is directly toxic to human retinal pigment epithelial cells when exposed to the cells for 7 days. On the contrary, retinal ganglion cells were damaged in a time-dependent manner by the more mechanical rather than toxic effects of PFCL.[4] Chemical toxicity manifests as macrophage and fibroblastic proliferation with preretinal membrane formation.[5]

We used PFCL to prevent subretinal blood under the macula and to tamponade the giant tear postoperatively. Our case suggests that use of PFCL as short term tamponade is safe and can lead to good visual outcome in selected cases.

References :

1. Sirimaharaj M, Balachandran C, Chan WC, Hunyor AP, Chang AA, Gregory-Roberts J, et al. Vitrectomy with short term postoperative tamponade using perfluorocarbon liquid for giant retinal tears. Br J Ophthalmol. 2005 Sep;89(9):1176-9
2. Lewis H, Sanchez G. The use of perfluorocarbon liquids in the repositioning of posteriorly dislocated intraocular lenses. Ophthalmology. 1993 Jul;100(7):1055-9.
3. Elliott D, Singh CN, Garcia-Valenzuela E, Ito Y, Abrams GW. Changes in retinal sensitivity from retained subretinal perfluorocarbon liquid. Retina. 2009 Feb;29(2):248-50.
4. Inoue M, Iriyama A, Kadonosono K, Tamaki Y, Yanagi Y. Effects of perfluorocarbon liquids and silicone oil on human

retinal pigment epithelial cells and retinal ganglion cells. Retina. 2009 May;29(5):677-81.

5. Velikay M, Wedrich A, Stolba U, Datlinger P, Li Y, Binder S. Experimental long-term vitreous replacement with purified and nonpurified perflorodecalin. Am J Ophthalmol 1993; 116: 565-70.)

Correspondence:



Dr Jay Chabalani MS

LV Prasad Eye Institute

Banjara Hills, Hyderabad

Email: jay.chhablani@gmail.com

Plateau Iris

Dr Tarannum Mansoori, MS

The term plateau iris was first used in 1958 to describe the configuration of the iris in a 44 year old man who had normal anterior chamber depth (ACD), flat iris plane and a sharp backward curvature of the peripheral iris. [1] Wand et al [2] differentiated "plateau iris configuration" from the "plateau iris Syndrome". The "configuration" refers to a preoperative condition in which gonioscopically confirmed angle-closure occurs, but the iris plane is flat and the ACD is not shallow axially. "Plateau iris syndrome" refers to a postoperative condition in which a patent iridectomy has removed the relative pupillary block, but gonioscopically confirmed angle closure persist without shallowing of the ACD axially. The level of the iris stroma in relation to the angle structures, referred to as the height of the plateau, differentiates the 2 subtypes of plateau iris syndrome (Figure 1).

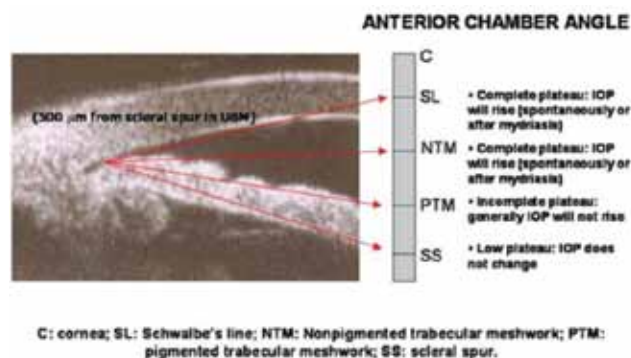


Figure 1: The position of plateau iris. Courtesy: Ritch R, Lowe RF. Angle closure glaucoma – clinical types: Ritch R, Shields MB, Krupin T. The glaucomas . Saint Louis: Mosby ; 1996, p 821-40.

In the complete syndrome, the angle is occluded to the upper trabecular meshwork or the Schwalbe line and intraocular pressure (IOP) rises. Incomplete plateau occludes the angle to mid level, leaving the upper portion of the filtering meshwork open and IOP unchanged. This latter situation is far more common and is clinically important because these patients can develop peripheral anterior synechiae (PAS) and synechial angle closure years after a successful iridotomy.

DIAGNOSIS

Patients with plateau iris tend to be female, in their 30-50s, hyperopic, and often have a family history of angle-closure glaucoma. Patients may present with angle closure, either spontaneously or after pupillary dilation. More commonly, the diagnosis of plateau iris configuration is made on routine examination.

Slit lamp examination of patients with plateau iris usually shows normal ACD with a flat or slightly convex iris surface. On gonioscopy, the angle is extremely narrowed or closed, with a sharp drop-off of the peripheral iris. When indentation gonioscopy is performed, the double-hump sign is seen (Figure 2). The more peripheral hump is determined by the ciliary body propping up the iris root, and the more central hump represents the central third of the iris resting over the anterior lens surface. The space between the humps represents the space between the ciliary processes and the endpoint of contact of the iris to the anterior lens capsule, resulting in sinuous configuration (sign wave sign).

More force often is needed to open the angle on indentation gonioscopy than on pupillary block angle closure.

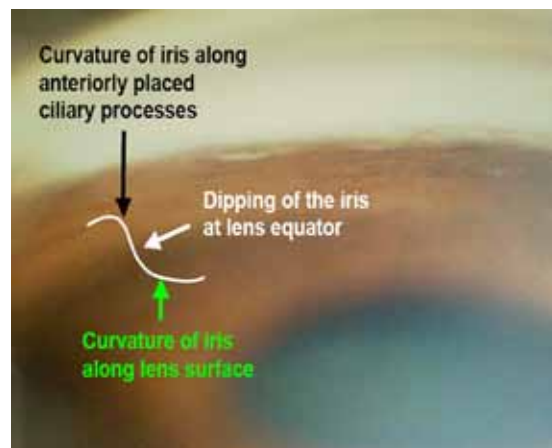


Figure 2: Gonioscopy shows the classic "double-hump" sign, with the peripheral hump created by the ciliary body pushing the iris root forward and the central hump created by the iris sitting on top of the anterior lens capsule.

Ultrasound biomicroscopy (UBM) plays a fundamental role in the diagnosis of plateau iris, as this modality can definitely confirm the anatomic abnormalities of the ciliary body. UBM will show anteriorly directed ciliary processes and in some cases a shortened, thickened iris root that is inserted in an anterior position in the ciliary body. [3] In a study, it was found that the mean ACD in patients with plateau iris was significantly smaller than the ACD in patients with pupillary block (2.04 mm + 0.3mm vs 2.17 +0.3 mm, p = 0.001). These findings go against the common thinking that the ACD in plateau iris is normal or relatively deep. The shallow ACD in plateau iris may be explained by the fact that the anterior position of the ciliary processes produce an anterior rotation of the lens which is also the same condition that produces pupillary block. [4]

EPIDEMIOLOGY

The exact prevalence of plateau iris is unknown. However, reportedly, it accounts for more than half of young patients with recurrent angle closure. The diagnosis of plateau iris should be suspected when angle closure occurs in patients who are young or myopic and when angle narrowing persists despite iridotomy. Stieger et al found the prevalence of plateau iris with recurrent angle-closure symptoms to be 54%, despite initial iridotomy or iridectomy.[5] In a study from Singapore, Kumar et al used UBM to show that approximately one-third of patients over the age of 50 with primary angle closure had a plateau iris after laser iridotomy[6] (Figure 3). There is also evidence to suggest that this anatomical predisposition may be familial with an autosomal dominant inheritance pattern.[7]

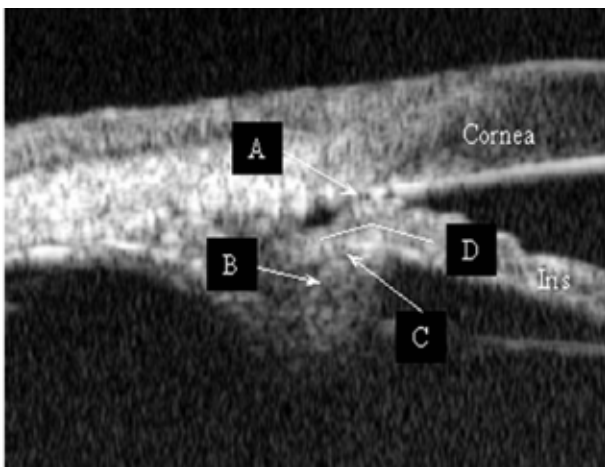


Figure 3: UBM image of a quadrant of plateau iris showing A. Irido-angle contact, B. Anteriorly directed ciliary process, C. Absent ciliary sulcus, D. Iris angulation Reproduced from KumarRS et al [6]

PATHOPHYSIOLOGY

In plateau iris, the pars plicata may be large and anteriorly positioned, mechanically positioning the peripheral iris against the trabecular meshwork. In addition, the iris root is inserted anteriorly on the ciliary face further crowding the anterior chamber angle. The iris crowding of the angle obstructs aqueous flow via the trabecular meshwork and may lead to angle-closure glaucoma.

Differential diagnosis

- Pupillary block (relative or absolute)
- Iridociliary cysts (“pseudoplateau iris”)
- Peripheral anterior synechiae
- Nanophthalmos

TREATMENT

In a newly diagnosed plateau iris patient, the initial strategy is to prevent significant spontaneous mydriasis. Pilocarpine eye drop may produce iris thinning and facilitate angle opening in some cases.

Argon laser peripheral iridoplasty (ALPI) is the procedure of choice to effectively open an angle that remains occluded after successful laser iridotomy. The procedure consists of placing laser burns on the surface of the peripheral iris to contract the iris stroma between the site of the burn and the angle. A spot size of 200 to 500 μm , a duration of 0.2 to 0.6 seconds, and a power of 150 to 300 mW can be used to perform this procedure. The result is iris stromal tissue contraction and compaction that physically widens the angle and prevents the apposition of the peripheral iris against the trabecular meshwork.

If angle closure persists despite sufficient peripheral laser iridoplasty, surgical intervention in the form of trabeculectomy, or tube-shunt implantation surgery may be needed to open the anterior chamber angle, allow bypass of aqueous flow, and control IOP.

PROGNOSIS

The prognosis for patients with plateau iris is generally good, provided the condition is recognized before vision loss occurs. Regular follow up with serial gonioscopy ensures that the proper interventions and treatment modalities are initiated when necessary because angle-closure may develop years after successful iridotomy or iridoplasty.

REFERENCES:

1. Tornquist R. Angle -closure glaucoma in an eye with a plateau type of iris. *Acta Ophthalmol* 1958; 36: 419-23.
2. Wand M, Grant WM, Simmons RJ, Hutchinson BT. Plateau iris syndrome. *Trans Sect Ophthalmol Am Acad Ophthalmol Otolaryngol.* 1977 ; 83 :122-30.
3. Pavlin CJ, Ritch R, Foster FS. Ultrasound biomicroscopy in plateau iris syndrome. *Am J Ophthalmol.* 1992 ;113:390-5.
4. Mandell MA, Pavlin CJ, Weisbrod DJ, Simpson ER. Anterior chamber depth in plateau iris syndrome and pupillary block as measured by ultrasound biomicroscopy. *Am J Ophthalmol.* 2004 ;137:1169-70; author reply
5. Stieger R, Kniestedt C, Sutter F, et al. Prevalence of plateau iris syndrome in young patients with recurrent angle closure. *Clin Experiment Ophthalmol.* 2007; 35: 409-413.
6. Kumar RS, Baskaran M, Chew PT, et al. Prevalence of plateau iris in primary angle closure suspects an ultrasound biomicroscopy study. *Ophthalmology.* 2008; 115: 430-434.
7. Etter JR, Affel EL, Rhee DJ. High prevalence of plateau iris configuration in family members of patients with plateau iris syndrome. *J Glaucoma.* 2006; 15 : 394-398.

Correspondence:



Dr Tarannum Mansoori

Anand Vitreo-Retina Institute

Habsiguda, Secunderabad

Email: tarannummansoori@yahoo.com

Retinal Optical Oherence Tomography

Dr Tandava Krishnan Panakanti; Dr Rajyalakshmi Ravikoti

Introduction: Optical Coherence Tomography (OCT) is a non invasive imaging modality useful for identification of lesions in the macula, optic disc and the anterior segment.¹ It provides a high resolution, in vivo optical biopsy of the tissue being scanned using the principle of optical interferometry.^{2,3} OCT can be in the form of Time domain OCT (TD OCT) or Fourier domain OCT.⁴ Fourier domain OCT is again subdivided into Spectral Domain OCT (SD OCT) which uses a spectrometer and a line scan camera for image acquisition and Swept source OCT which has a rapidly tunable LASER source for the same purpose. 1

Principle: In TD OCT a beam of light emitted from a diode source of wavelength 840 nm is split towards the eye and a mobile reference mirror. Light is reflected back (from eye and the mirror), sequentially detected by a photo detector and then sent to the display (Figure 1).

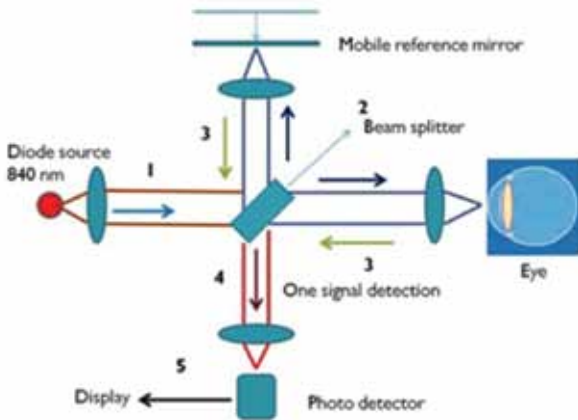


Figure 1: The light from a diode source(1) is split towards the eye and the mobile reference mirror (2), reflected back (3) and are detected sequentially i.e. one by one (4) and then sent to the display (5).

Fourier domain OCT works on a similar principle as that of a TD OCT with 2 important differences. The reference mirror is stationary and all the signals are detected simultaneously, thereby reducing the image acquisition time (Figure 2). This also enhances the number of scans obtained per second and improves the axial resolution of the scan (Figure 3).

Interpretation: Information gathered from OCT can be qualitative or quantitative in nature. Qualitative data can be in the form of identification of retinal pathologies like vitreo macular traction, macular holes, cystoid macular oedema and choroidal neovascular membrane. 1Quantitative data such as foveal thickness are used to make treatment decisions like in conditions such as Age related macular degeneration, diabetic macular oedema ,retinal vein occlusions and

macular holes. 5-8,14 Likewise retreatment decisions are also based to some extent on the foveal thickness obtained by an OCT scan.

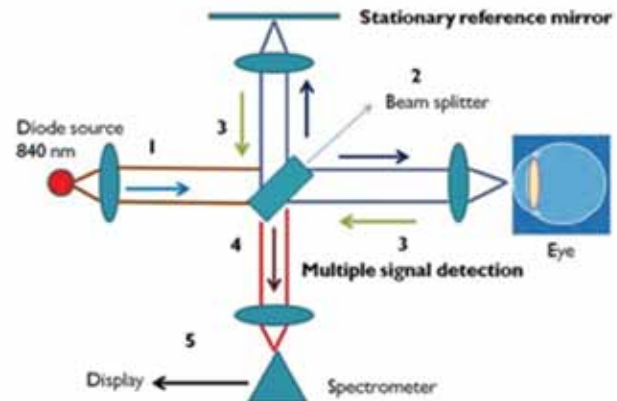


Figure 2: The light from a diode source (1) is split towards the eye and the stationary reference mirror (2), reflected back (3) and are detected simultaneously (4) and then sent to the display (5).

	Time domain OCT	Spectral domain OCT
Reference arm	Mobile	Stationary
Interpretation	Sequential	Simultaneous
Scans per second	400	18000-50000
Axial resolution (in microns)	8-10	5-8

Figure 3: The presence of stationary reference mirror and simultaneous interpretation results in lesser acquisition time, greater number of scans and better axial resolution of SD OCT.

Qualitative interpretation of OCT begins with the identification of different retinal layers. The nerve fibre layer is the hyper reflective superficial layer which is most prominently noted nasal to the fovea in the area corresponding to the papillo-macular bundle. Beneath this are a hypo reflective ganglion cell layer and the hyper reflective inner plexiform layer. This is followed by the hypo reflective inner nuclear layer and the hyper reflective outer plexiform layer. We next note the hypo reflective outer nuclear layer and the hyper reflective external limiting membrane. The inner segment outer segment junction (IS-OS junction) of photoreceptors is seen next as a hyper reflective membrane. The Retinal pigment epithelium – Chorionicapillaris complex (RPE –CC complex) forms the outer most hyper reflective membrane. The gap between the

IS-OS junction and the RPE-CC complex is best delineated at the fovea because of the increased height of the outer segment of the cones at the fovea (Figure 4).

A systematic qualitative assessment of the retinal OCT comprises of four components, namely vitreo-retinal (VR) interface, foveal contour, retinal architecture and RPE –CC complex.

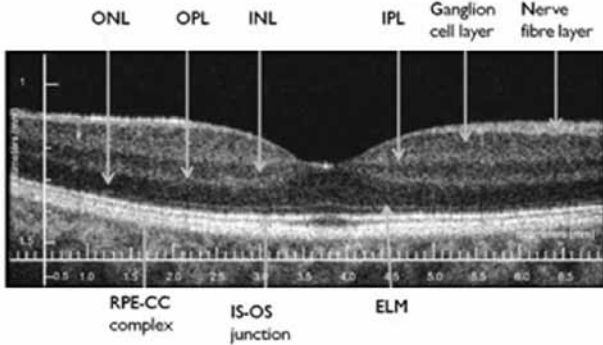


Figure 4: Interpretation of different retinal layers on OCT. IPL – Inner plexiform layer; INL- Inner nuclear layer; OPL- Outer plexiform layer; ONL- Outer nuclear layer; ONL- Outer nuclear layer; ELM- External limiting membrane; IS-OS junction – Inner segment outer segment junction; RPE –CC complex- Retinal pigment epithelium choriocapillaris complex.

Vitreo-Retinal interface:The normal VR interface is without any overt traction (Figure 5). Traction if present can be focal (Figure 6) or over a broad area (Figure 7).

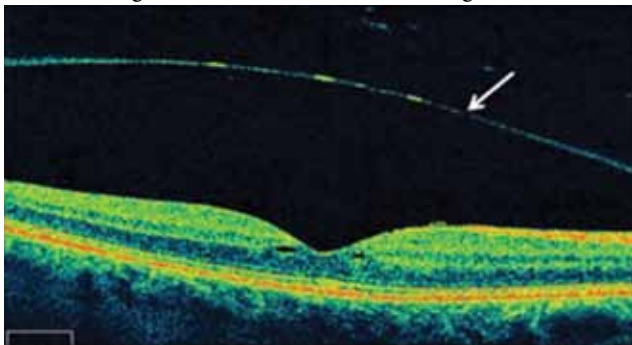


Figure 5: Vitreo retinal (VR) interface with no traction. Note the membrane (Arrow) in the vitreous completely free from any form of connection with the VR interface

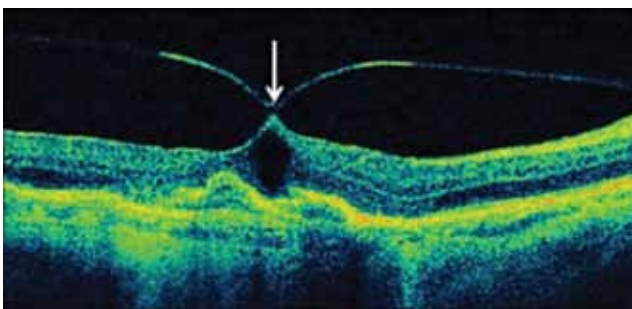


Figure 6: Vitreo retinal (VR) interface with focal traction. Note the membrane (Arrow) in the vitreous causing focal tenting of the VR interface at the fovea causing loss of foveal contour

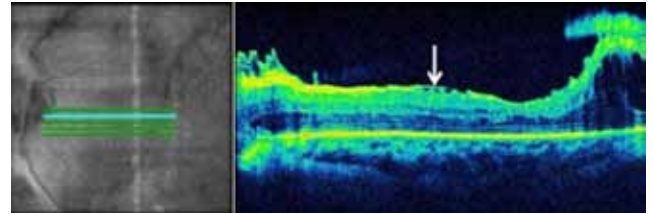


Figure 7: Vitreo retinal (VR) interface with broad adhesions. Note the membrane (Arrow) causing traction over a wide area of macula causing ILM wrinkling and elevation of the retina on the right side of the image

Foveal contour: The normal foveal contour is concave in nature (Figure 4, 5). The contour can be obliterated by a tractional force pulling from vitreous (Figure 6) or by a lesion pushing it from below like a Choroidal neovascular membrane (CNVM) (Figure 8). The foveal contour can also be replaced by a macular hole which can be full thickness (Figure 9) or lamellar in nature. Lamellar holes are further sub divided into inner lamellar holes (Figure 10) and outer lamellar holes (Figure 11)

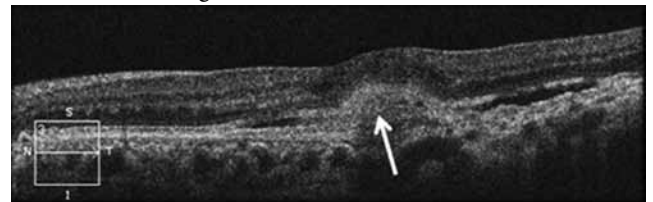


Figure 8: Foveal contour is lost because of a pushing mechanism i.e CNVM (arrow) from below.

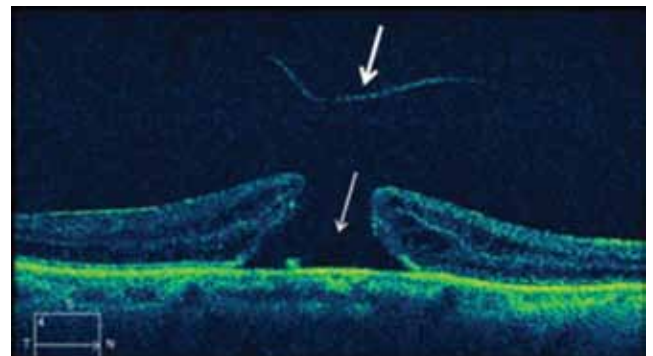


Figure 9: A full thickness macular hole is noted (small arrow). Also note the complete separation of the vitreous from retina (large arrow). This is noted in a stage 4 macular hole.

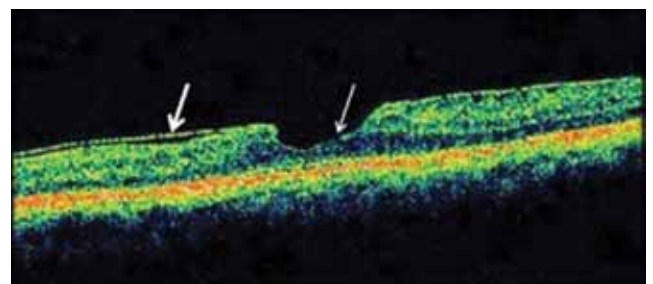


Figure 10: OCT shows inner lamellar hole (small arrow). Also note the epiretinal membrane (Large arrow) which might be the aetiology for the lamellar hole.

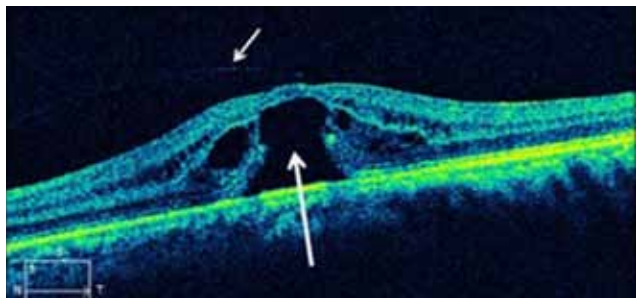


Figure 11: OCT shows a outer lamellar hole (large arrow). The membrane in vitreous (small arrow) causing focal traction over fovea is the possible aetiology.

Retinal architecture: Different retinal layers can be delineated in the normal retinal architecture (Figure 4). The architecture can be altered in the presence of fluid, exudates (Figure 12) or schisis (Figure 13). Fluid may be intra retinal (Figure 12,14) or sub retinal (Figure 14,15). Intra retinal fluid may be diffusely distributed (Figure 12) or may be localized in form of cysts (Figure 14).

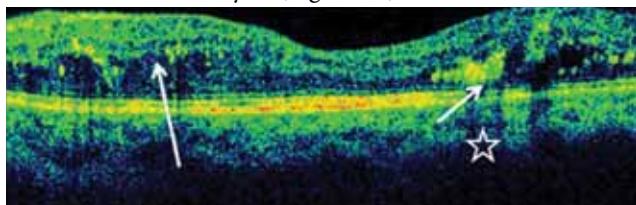


Figure 12: OCT shows diffuse thickening of retinal layers due to fluid (large arrow). Also seen are the hard exudates (small arrow) causing posterior shadowing (star)

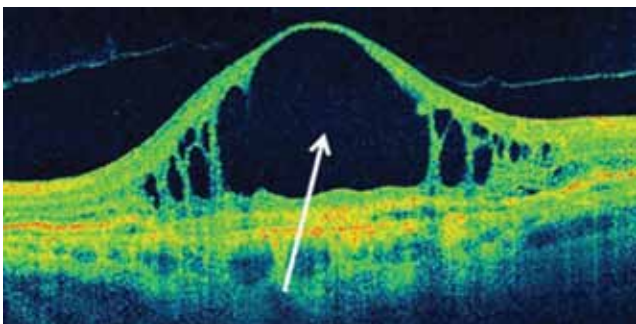


Figure 13: OCT shows large schitic cavity (arrow)

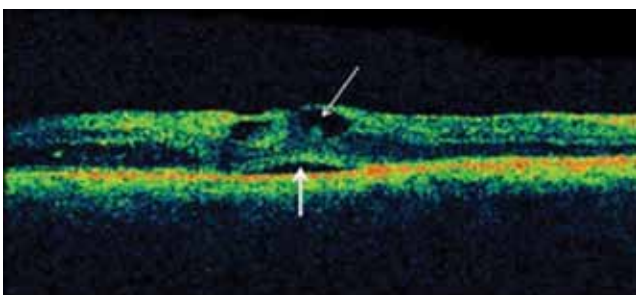


Figure 14: Oct shows intra retinal cystic (fluid filled) cavity (thin arrow) and neuro sensory detachment (thick arrow) suggestive of sub retinal fluid.

RPE-Choriocapillaris complex: The RPE-choriocapillaris complex is a normally a straight line located posterior to the neuro-sensory retina. It can be altered and appear

bumpy (Drusen)[Figure 16], fusiform shaped (CNVM) [Figure 17] or abnormally elevated (Pigment epithelial detachment{PED}). PED may be further classified as Serous (when the posterior layer is well delineated) (Figure 18) and haemorrhagic(when the posterior layer is not well delineated). The posterior layer is partly visible in fibrovascular PED.

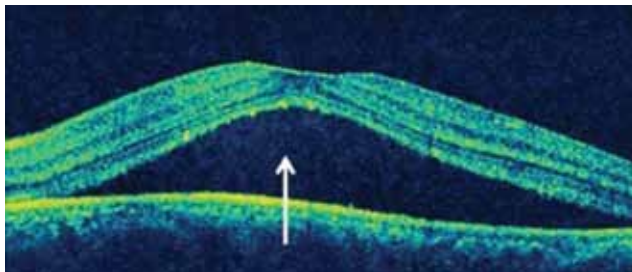


Figure 15: OCT shows large fluid filled area in the sub retinal space (arrow) in an eye with central serous retinopathy

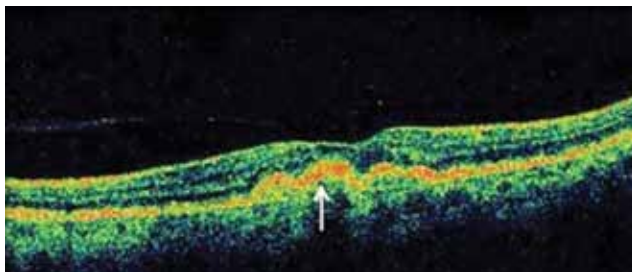


Figure 16: OCT shows bumpy RPE (arrow) in an eye with Dry ARMD. Figure 17: The figure shows a fusiform elevation of RPE-choriocapillaris complex (thick arrow) suggestive of a CNVM. Also note the neuro sensory detachment (thin arrow) indicative of either sub retinal fluid or the effect of mechanical tenting of CNVM.

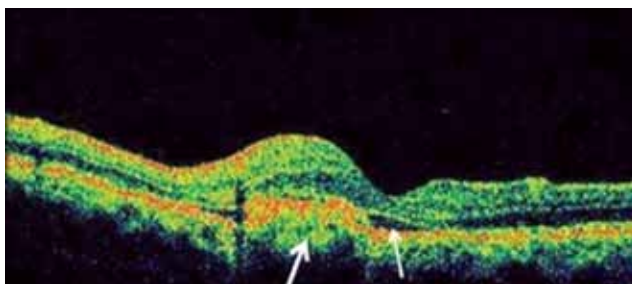


Figure 17: The figure shows a fusiform elevation of RPE-choriocapillaris complex (thick arrow) suggestive of a CNVM. Also note the neuro sensory detachment (thin arrow) indicative of either sub retinal fluid or the effect of mechanical tenting of CNVM.

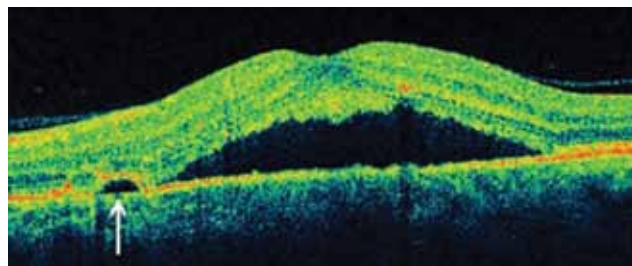


Figure 18: The figure shows an elevated RPE-choriocapillaris

complex. Note that the posterior layers are well delineated (Arrow) indicative of the serous nature of PED. Also note the Neuro sensory detachment.

Quantitative assessment of OCT can be based on measurements generated by the OCT machine or on manual measurement using the calipers. Treatment/retreatment decisions are made based on these measurements in conditions like Age related macular degeneration and retinal vein occlusions. Distortion of retinal architecture can result in improper machine generated measurements. Care must be taken to ensure that appropriate landmarks have been used for the measurements. (Figure 19,20,21). It is advisable to reconfirm the measurements manually using the calipers. 9

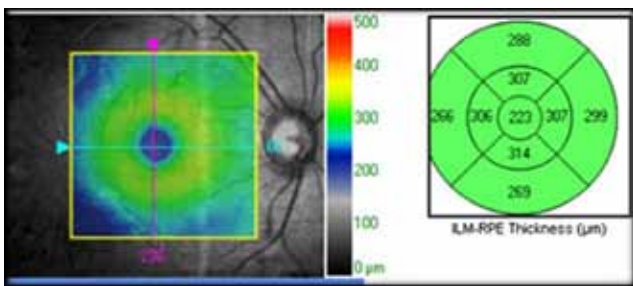


Figure 19: Note that the point of intersection of the horizontal and vertical line pass through the central blue circle representing the fovea. This suggests that the measurements are taken from the correct anatomical location.

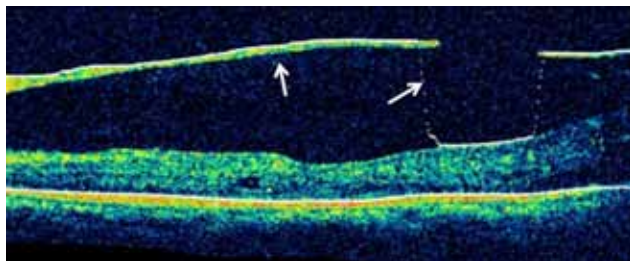


Figure 20: Note that the presence of membrane in vitreous results in inappropriate delineation of the vitreous macular interface (arrows) resulting in incorrect measurement of thickness.

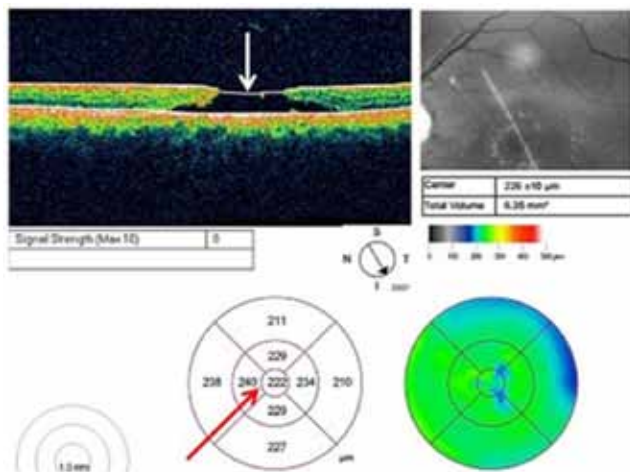


Figure 21: In a case of macular hole, inappropriate delineation

of vitreo macular interface (White arrow) results in incorrect measurement of foveal thickness (Red arrow).

Application of OCT in clinical situations- What literature says:

Diabetic macular oedema (DMO):6,10 OCT is useful in cases of DMO for the following purposes:

- Detection of macular oedema
- Quantification of macular oedema (retinal thickness)
- Evaluation of vitreo-macular interface
- Monitoring of macular oedema after treatment

The various patterns of macular oedema described include diffuse retinal thickening, cystoid macular oedema, neuro-sensory detachment, vitreo macular traction (VMT) without tractional retinal detachment (TRD) and VMT with TRD. (Figures 22-26)

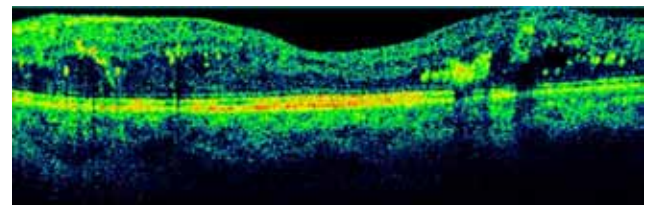


Figure 22: Diffuse retinal thickening

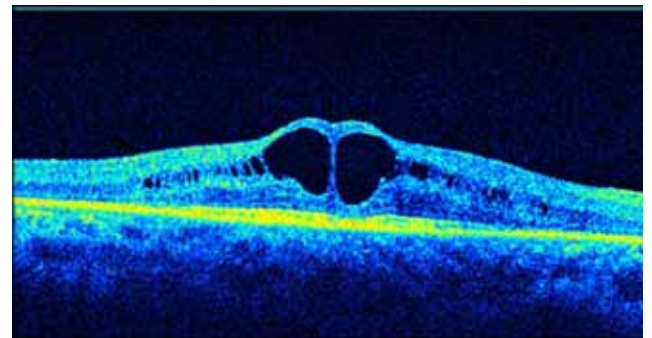


Figure 23: Cystoid macular oedema

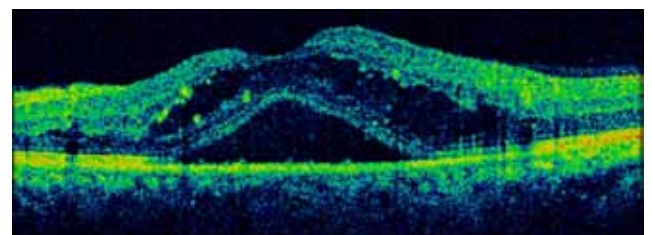


Figure 24: Neuro sensory detachment

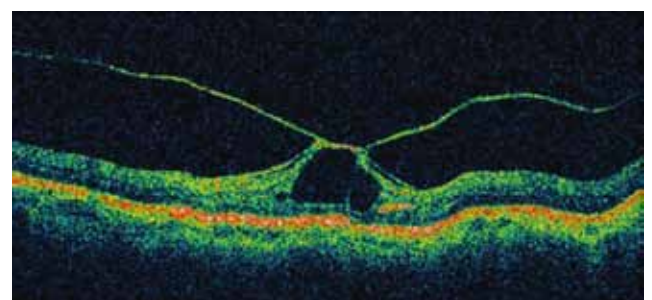


Figure 25: VMT without TRD

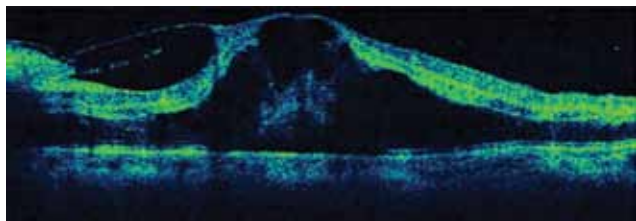


Figure 26: VMT causing TRD

The management would be medical for eyes without VMT and surgical for eyes with VMT. Anti VEGF agents are considered for eyes with centre involving macular oedema with visual acuity less than 6/12 while laser is considered initially for centre sparing macular oedema with preserved visual acuity. OCT is also a useful guide to assess the response to treatment during follow ups where retreatment is considered in case of foveal thickness being greater than 250 microns.

Retinal vein occlusions: (RVO)7,8,11,12 : Treatment with anti VEGF agents (6 injections on monthly basis) are considered in case of CRVO or BRVO with macular oedema if the visual acuity is less than 6/12 and the foveal thickness is more than 250 microns. Similar criteria are also used during follow ups for retreatment decisions.

Age related macular degeneration (ARMD):5 OCT is useful in ARMD to assess the extent of retinal thickness and to look for sub retinal fluid. After 3 loading dose injections are given, retreatment decisions are made based on:

- 5 letter loss with fluid in macular area(OCT)
- ≥ 100 μ increase in central retinal thickness (OCT)
- New onset CNVM
- New onset macular haemorrhage
- Persistent macular fluid (OCT)

Hence, we note that OCT has a key role to play in decisions of retreatment in cases of ARMD.

Polypoidal choroidal vasculopathy:13 OCT helps in identifying cases of PCV. Haemorrhagic PED, especially when associated with a greater height of PED is indicative of PCV. Moreover, linear arrangement of serial scans reveal the inner aspect of a polyp with separation of serous and corpuscular elements (Haematocrit sign).

Macular Hole:14 OCT helps to prognosticate the outcome of surgeries in cases of macular hole. Patients with lesser base diameter and minimum diameter tend to have a greater probability of hole closure.

To summarise, a systematic interpretation of OCT (qualitative and quantitative) (Figure 27) not only helps in diagnosis but is also useful in making treatment decisions and prognostication.

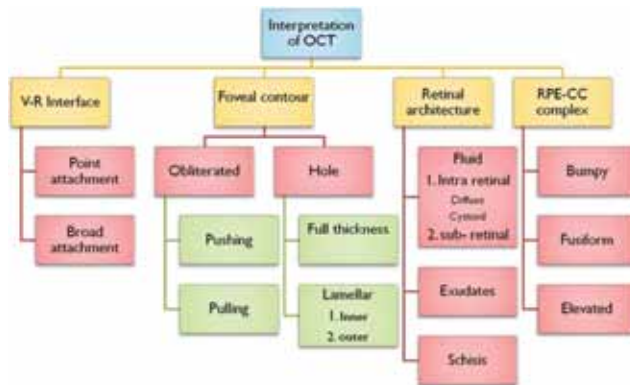


Figure 27: Qualitative interpretation of OCT- Flow chart

REFERENCES:

1. Ho J, Sull AC, Vuong LN, Chen Y, Liu J, Fujimoto JG, et al. Assessment of artifacts and reproducibility across spectral- and time domain optical coherence tomography devices. *Ophthalmology* 2009; 116:1960-70.
2. Sadda SR, Wu Z, Walsh AC, Richine L, Dougall J, Cortez R, et al. Errors in retinal thickness measurements obtained by optical coherence tomography. *Ophthalmology* 2006; 113:285-93.
3. Ray R, Stinnett SS, Jaffe GJ. Evaluation of image artifact produced by optical coherence tomography of retinal pathology. *Am J Ophthalmol* 2005; 139:18-29.
4. Ho J, Castro DP, Castro LC, Chen Y, Liu J, Mattox C, et al. Clinical assessment of mirror artifacts in spectral-domain optical coherence tomography. *Invest Ophthalmol Vis Sci* 2010; 51 :3714-20.
5. Mitchell P, Korobelnik JF, Lanzetta P, Holz FG, Prunte C, SchmidtErfurth U, et al. Ranibizumab (Lucentis) in neovascular age-related macular degeneration: evidence from clinical trials. *Br J Ophthalmol* 2010; 94:2-13.
6. Aiello LP, Beck RW, Bressler NM, Browning DJ, Chalam KV, Davis M, et al. Rationale for the diabetic retinopathy clinical research network treatment protocol for center-involved diabetic macular edema. *Ophthalmology* 2011; 118:e5-e14.
7. Keane PA, Sadda SR. Retinal vein occlusion and macular edema – critical evaluation of the clinical value of ranibizumab. *Clin Ophthalmol* 2011; 5:771-81 .
8. Mitry D, Bunce C, Charteris D. Anti-vascular endothelial growth factor for macular oedema secondary to branch retinal vein occlusion. *Cochrane Database Syst Rev* 2013; 1 :CD009510
9. Chhablani J, Krishnan T, Sethi V, Kozak I. Artifacts in optical coherence tomography. *Saudi J Ophthalmol.* 2014 Apr;28(2):81-7.
10. F Bandello et al. New approaches for the treatment of diabetic macular oedema: recommendations by an expert panel. *Eye* (2012) 26, 485-493
11. Campochiaro PA, Brown DM, Awh CC, et al. Sustained Benefits from Ranibizumab for Macular Edema following Central Retinal Vein Occlusion: Twelve-Month Outcomes of a Phase III Study. *Ophthalmology* 2011.
12. Brown DM, Campochiaro PA, Bhisitkul RB, et al. Sustained Benefits from Ranibizumab for Macular Edema Following Branch Retinal Vein Occlusion: 12-Month Outcomes of a Phase III Study. *Ophthalmology* 2011
13. Imamura Y, Engelbert M, Iida T, Freund KB, Yannuzzi LA. Polypoidal choroidal vasculopathy: a review. *Surv Ophthalmol.* 2010 Nov-Dec;55(6):501-15
14. Ullrich S, Haritoglou C, Gass C, Schaumberger M, Ulbig MW, Kampik A. Macular hole size as a prognostic factor in macular hole surgery. *Br J Ophthalmol.* 2002 Apr;86(4):390-3.

Correspondence:



Tandava Krishnan Panakanti
 Vasani Eye Care, Hyderabad
 Email: krishnanpanakanti@yahoo.com

Minimally invasive eye lid & facial rejuvenation: An evolving world

Dr Shubhra Goel MD

Facial rejuvenation, the hypothetical reversal of the aging process, encompasses any cosmetic procedure, that restores a youthful appearance to the face. With continually advancing knowledge and refinement in surgical techniques, the oculofacial plastics field has become less invasive, keeping pace with the changing world of surgery to the mini or nano world.

Why do we need facial rejuvenation?

The basic shape of the face is determined by the hard tissues (bone, teeth, cartilage), while the overlying skin and soft tissues (fat, muscle, connective tissue). These cephalometric parameters change and descend with age and environmental influences. Specific changes, initially appearing in the upper face followed by the lower face and neck, can be considered within three different zones (upper, middle, and lower) of the face. In the upper third, the lateral eyebrows descend (brow ptosis) below the supraorbital rim, and further exacerbates upper lid skin hooding (dermatochalasis). Weakening of the orbital septum permits intraorbital fat prolapse, which manifests as eyelid fat bags. The levator aponeurosis becomes attenuated, resulting in upper eyelid ptosis. In the midface, fat absorption diminishes the smooth cushion between the lower lid and malar prominence, resulting in infra-orbital hollowing. In addition to the anatomic changes above, there is continuous aging at the skin level. The skin becomes dry, dull, thin, wrinkled, pigmented, and lax.

How can we achieve eyelid and facial rejuvenation?

Complete facial rejuvenation not only refers to surgery, but also skin optimization. This is achieved via resurfacing to revitalize skin texture (using cosmeceuticals, lasers, chemical peels, dermabrasion), refilling depressions with fillers and fat transfer, and relaxing the muscles with botox to smooth wrinkles. The surgical component entails releasing and redraping descended facial tissues back to their original anatomical positions.

Forehead and eyebrow lift: Long-lasting elevation of the eyebrows and the elimination of forehead rhytids are the ideal. In the endoscopic lift, dissection is carried out over the frontal bone down to the supraorbital rim to release the arcus marginalis. Resection of hyperdynamic corrugator and procerus muscles is performed if indicated. Care is taken to avoid dissecting the periosteum attachments between the corrugators that may lift the medial brow and result in a surprised look. Advantages of the endoscopic approach are minimal scars, decreased alopecia, less scalp sensory changes compared to conventional coronal lifting,

and allows simultaneous rejuvenation of the forehead and eyebrows. The transpalpebral or internal browlift, ideal for mild to moderate brow ptosis, is a natural extension of eyelid surgery in which the descended lateral brow is secured above the supraorbital rim through the blepharoplasty incision. Lateral brow fat sculpting is less often performed as maintaining or restoring volume is crucial to creating a more youthful appearance, as opposed to a hollow look. Suborbicularis dissection is performed to 1.0-2.0 cm above the superolateral orbital rim. The retroorbicularis oculi fat (ROOF) at the level of the inferior brow hairs is anchored with suture to the frontal periosteum. Placement height to the periosteum is adjusted according to gender and the amount of brow ptosis. The Transbleph Endotine absorbable implant, placed through a subperiosteal dissection with ledging of the periosteum and soft tissues over the implant, may also support a ptotic brow via multipoint fixation.

Blepharoplasty: Blepharoplasty is derived from Greek "Blepharon" (eyelid) and "Plastos" (formation). Typical lid crease markings are 9-11 mm centrally from the lid margin in women, and lower at 8-10 mm above the margin in men, respecting the rounder contour of the female lid crease as opposed to the flatter contour in males. After a skin-muscle flap is removed, any prolapsed orbital fat may be debulked by opening the orbital septum. However, with considerations of volume loss in the aging face, often it is more favourable to thermally sculpt mild to moderate fat prolapse with a radiofrequency or monopolar tip over an intact septum. Not only does this less invasive approach expedite surgery time and minimize orbital hemorrhage as the septum is not violated, but it also creates a fuller youthful look to the eyelids by minimizing excess fat removal. Upper lid blepharoplasty can also be enhanced by dissecting medially over the glabella to release and weaken hyperdynamic glabellar muscles that create unfavorable forehead creases (Figure-1).

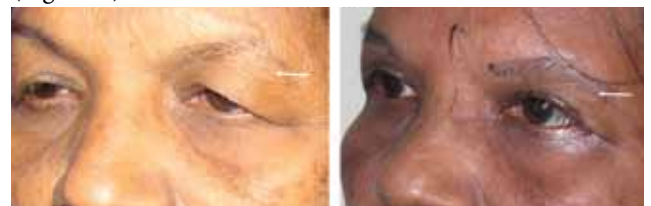

Figure-1 : A 40 year old lady with upper lid blepharoplasty and internal brow lift for her dermatochalasis (arrow) - 3day postoperative.

For lower eyelid dermatochalasis with fat prolapse, the optimal minimally invasive technique entails transconjunctival resection or repositioning of fat pads,

with or without skin excision and lateral suspension of the orbicularis oculi. The transconjunctival approach avoids an external scar and is optimal for younger patients with fat prolapse and negligible dermatochalasis. The everted palpebral conjunctiva of the lower lid is incised with several 4-5mm openings over the areas of prolapsed fat. Through these small pockets, the desired fat pads are isolated and debulked. These smaller incisions allow for faster recovery, less chance for eyelid retraction, and decreased postoperative chemosis and swelling. Again, the hollow look should be avoided by conservative removal of fat. In some cases, the fat pads can be isolated as pedicles that are transposed supra- or subperiosteally over the orbital rim to augment deep tear trough deformities. If there is associated skin laxity, excision of skin with lateral suspension of the orbicularis muscle is recommended. A subciliary skin incision extending to the lateral canthus with elevation of a skin flap is performed. A small incision through the orbicularis muscle at the lateral raphe is made through which lateral release and mobilization of the orbicularis muscle flap is performed. A canthus-sparing lateral canthopexy creates horizontal tightening through this minimal incision without disrupting the natural shape of the eye, followed by resuspension of the orbicularis flap to the lateral periosteum. Appropriate tightening of the orbicularis flap improves the eyelid creases, and any excessive skin is then redraped and conservatively excised. If there is mainly mild skin laxity without muscle creases, a minimally invasive skin pinch can be utilized. A hemostat is used to pinch a narrow horizontal strip of lax subciliary skin, the excess removed with scissors, and the incision closed (Figure 2). By minimizing dissection within the various tissue planes of the lower lid, this greatly decreases the risk of cicatricial retraction and ectropion.

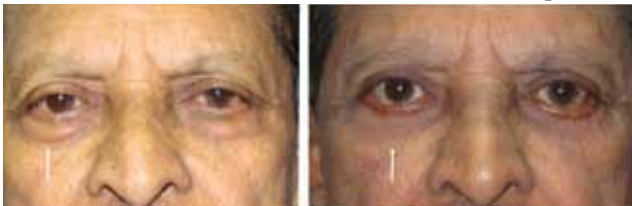

Figure-2: A 50 year old gentleman following lower lid blepharoplasty for his eyelid bags (arrow)

Small incision external levator repair and internal conjunctivomullerectomy surgery: Involutional ptosis is corrected by levator advancement or resection via external or internal approaches. Small incision external levator surgery has the benefits of less scarring, decreased operative time, and maximum tissue preservation. This technique is ideal for ptotic lids with minimal dermatochalasis, and incorporates all the steps for external levator surgery through a minimal 8-12 mm crease incision. This minimal approach is technically more challenging and requires adequate prior experience with full incision levator surgery. For mild ptosis ranging 1-3 mm, aponeurotic surgery may be unpredictable or difficult. Posterior conjunctival and Muller muscle resection is ideal in such cases. It is based on

the principle that levator plication occurs with advancement of Muller's muscle. The eyelid is everted over a retractor and a predetermined amount of conjunctiva and Muller's muscle excised using a Putterman clamp. The amount of resection is based on several available algorithms and a positive 2.5% phenylephrine test (increase in MRD1 by 1.5mm). This minimally invasive approach results in rapid healing, no scarring, and an excellent eyelid contour (Figure 3).

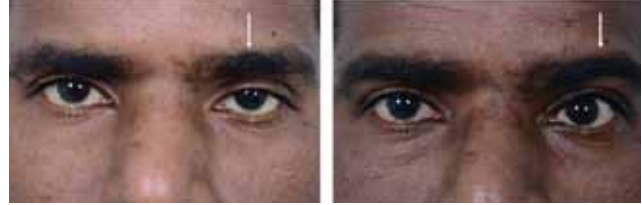

Figure-3: A 35 year old gentleman following left following left upper lid conjunctivomullerectomy ptosis correction for mild ptosis (arrow)

Midface and small-incision face lifting: Midfacial ptosis can be corrected in conjunction with eyelid surgery or with small-incision face lifting. Both open and endoscopic approaches have been well-documented. A simple technique of lateral suborbicularis oculi fat (SOOF) lifting and orbitomalar ligament suspension can be particularly useful when combined with eyelid surgery. This technique is simple, with less risk to surrounding neurovascular structures compared to techniques requiring periosteal elevation. Through a 10 mm lateral canthotomy incision, the inferior limb of the lateral canthal tendon is released, as well as the orbitomalar ligament in the preperiosteal plane over the inferolateral orbital rim. Superolateral resuspension of the SOOF to the periosteum of the zygoma lateral to the orbital rim results in elevation of the cheek over the malar prominence.

Face lifting has evolved significantly, from the era of total and composite rhytidectomy to minimally invasive techniques to plicate/resect the SMAS, and cannot be adequately covered in this overview. In the MACS (minimal access cranial suspension) lift, vertical suspension of the descended SMAS is achieved through plication with purse string sutures and anchoring to the temporalis fascia through preauricular and temporal hair line incisions. Two to three purse string sutures are typically placed for correction of neck and lower face descent. For midfacial ptosis, an additional suture suspends the malar fat pad. For patients with severe facial aging and descent, minimally invasive approaches may not be adequate.

Botox and fillers: These non-invasive options for facial rejuvenation are extremely popular and essential in any cosmetic practice. They are quick office procedures with minimal downtime and high satisfaction rates. Facial lines from aging can be static or dynamic creases, or a combination of both. Botulinum toxin A (Botox) inhibits the release of acetylcholine at the neuromuscular junction

and hence blocks muscle contraction to relax the dynamic facial lines. Botox is most commonly used in the upper face, and dermal fillers in the lower face. Botox diminishes the dynamic horizontal wrinkles in the forehead by targeting the frontalis muscles, the vertical glabellar rhytids by targeting the corrugator, depressor supercilii, and procerus muscles, and the periorbital “crow’s feet” lines by weakening the orbicularis oculi (Figure 4,5A,B). Other uses are for correction of platysmal bands, brow ptosis, and perioral lines. Botox is often used in conjunction with dermal fillers, peels, and lasers for optimal results. Absolute contraindications are coagulopathies, neuromuscular disorders, and pregnancy.

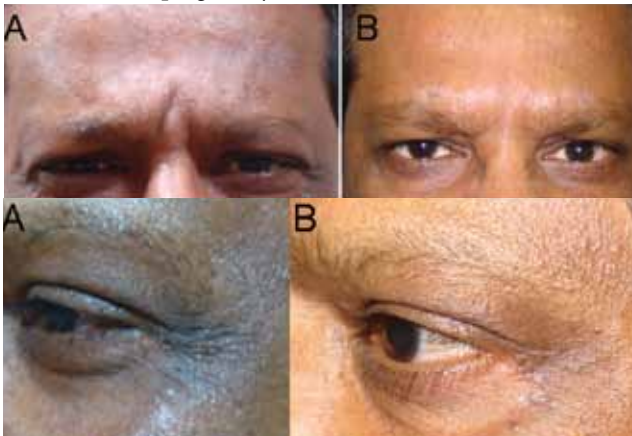

Figure-4: Botulinum toxin injections for frown and smile lines A-Pre injection ; B-Post injection

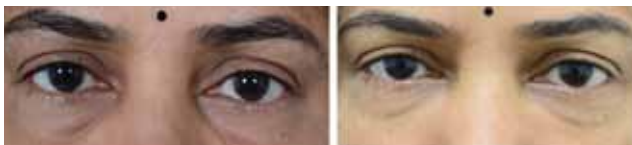

Figure-5A: Hyaluronic dermal fillers for lower lid tear troughs or hollows. A-Pre injection ; B-Post injection

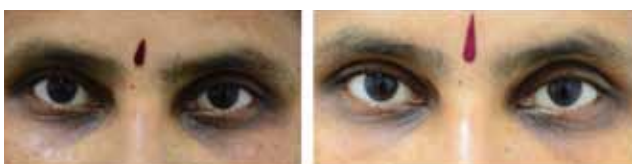

Figure-5B: Hyaluronic dermal fillers for circles. Note the decrease in the shadow effect. A-Pre injection ; B-Post injection

Dermal fillers, in contrast, address static facial rhytids. Fillers have progressed from the early collagen fillers to hyaluronic (Juvaderm, Restylane, Perlane) fillers, semi-permanent fillers like poly L-lactic acid (Sculptra), calcium hydroxylapatite (Radiesse), and beta TCP (Atlean), and permanent fillers like polymethylmethacrylate (PMMA) and silicone oils. The choice of filler depends on the location of the crease, as well as the severity, with deeper rhytids augmented with fillers of larger molecule size. Common areas treated are the glabellar rhytids, nasojugal folds, oral commissure, marionette lines, vertical lip lines, prejowl sulcus, and lip augmentation (Juvaderm, Restylane), nasolabial folds (Radiesse, Juvaderm, Restylane), midface

atrophy (Radiesse), and HIV lipodystrophy (Radiesse, Sculptra). Injection should be intradermal with smaller particle fillers and subdermal with larger particle fillers. The average duration for hyaluronic fillers is 6 (Restylane) to 12 months (Juvaderm), 9-18 months for Radiesse, and up to 2 years for Sculptra. Common filling techniques are linear threading, cross-hatching, and puncture filling.

Other noninvasive options: Skin resurfacing involves de-epithelialization of the epidermis and controlled damage to different levels of the dermis, depending on the amount of correction required, for enhancement of skin texture and pigmentation. Reepithelialization results in a smoother epidermis, and regeneration of collagen and elastin tightens and strengthens the damaged dermis.

Microdermabrasion: Dermabrasion was initially performed with a metal, diamond, or ruby grinder to resurface the skin. In contrast, microdermabrasion exfoliates only 10-15 microns off the epidermis. The open crystal system uses a hand-held device to propel a high-speed flow of aluminum oxide/sodium bicarbonate or sodium chloride crystals onto the skin, and the vacuum system suctions away dirt, dead cells, and used crystals (ie. Parisian peel). The closed system superficially abrades the skin, and is under negative pressure (closed loop) with the contaminated crystals collected in the canister for disposal. More recently, hydradermabrasion pairs mechanical exfoliation with infusion of peptides and antioxidants into the skin.

Chemical peels: Peels can be a useful adjunct to surgery to improve skin texture and tone, but also can be well utilized for rejuvenation when a patient is not yet interested in surgery. Various chemical combinations are applied to the skin to incite epidermal and dermal injury. Depending on the concentration and depth of application of the agent, the peel can be superficial (epidermis and dermoepidermal junction), or medium to deep extending into the papillary or reticular dermis, respectively. After the surface layers are removed, there is increased fibroblastic proliferation, decreased melanocyte proliferation and uniform distribution, and increased dermal regeneration of new collagen and elastin. Peels are often comprised of alpha and beta hydroxyl acids, trichloroacetic acids (15- 50%, higher concentration for deeper peels), phenol (Baker-Gordon formula), among others. The cosmoceutical market today carries a vast array of different formulations, with some popular lines being Obagi, Biomedics, Cellex-C, Skinceuticals, SkinMedica, and Neostrata. Selection of which cosmoceutical therapy to use for home skin care should be individualized for each patient, and can be determined with the assistance of a licensed aesthetician.

Lasers: Laser resurfacing is one of the fastest evolving modalities in the cosmetic industry. Lasers can be

divided into ablative and nonablative lasers, and are used for overall skin rejuvenation as well as selective lesion treatment. Ablative lasers heat and vaporize the water in the superficial skin layers in contrast to nonablative treatments that coagulate deeper epidermal and dermal tissues without removing superficial tissue. This preserves vital nutrients and glands within the skin layers, which facilitate healing and more rapid regeneration while also minimizing downtime. The gold standard ablative laser is the CO₂ 1060nm. However, as ablative lasers increase downtime, cost, and possible complications, nonablative lasers have risen to greater popularity. Nonablative lasers include Nd:YAG 1064, 1450nm, Diode 810nm, Q switched ruby 694nm, Erb:YAG 294nm, and Er:Glass 1540nm. Fractional photothermolysis delivers light in a matrix array of microbeams or pixels to create narrow beams or deep columns of tissue coagulation while sparing the tissue surrounding the columns. The preserved tissue between the coagulated columns facilitates more rapid healing and accelerates the regeneration of new collagen, in contrast to ablative lasers in which healing proceeds only from the periphery of ablated tissue. The Rhytec Portrait® PSR laser transfers nitrogen plasma energy to the skin using a non-contact technique. Palomar lasers include the Lux fractional photothermolysis laser (LUX 1540, 1440), Lux Deep IR, Fractional infrared laser, and Stralux IPL (intense pulsed light therapy). IPL uses high intensity pulses of visible light (xenon) and delivers multiple wavelengths in each pulse of light rather than a single wavelength. This allows the procedure to target several conditions simultaneously. Various handpieces adjust for different wavelengths of light energy to achieve skin tightening, hair removal, or pigment and vascular treatment. The Palomar Lux 1064 Nd:YAG may treat pigmented lesions even in skin types IV-V. Syneron (900nm diode) combines radiofrequency and light energy using a bipolar electrode, the Cutera Titan uses 1100-1300nm of infrared energy, and the Orion ST uses 800-1000nm of infrared energy. The recently released Matrix Fractional CO₂ combines the results of CO₂ laser with fractional photothermolysis and decreased downtime.

Radiofrequency energy: Radiofrequency systems deliver concentrated energy at the periphery of the electrode. Thermage delivers 225 J/cm² of energy, reaching temperatures of 55-70°Celsius, with uniform energy distribution across the entire electrode. Tissue heating occurs evenly at 2-3 mm beneath the skin surface. Disadvantages of Thermage were cost and risk of pain and burns from high temperatures at the skin surface. More recently, the FDA approved Radiage, which is inexpensive and easy to use. The Ellman Surgitron unit is used with special dome-shaped skin tightening probes that deliver 4 MHz high energy radiofrequency between 12-25 J/cm². Advantages are its safety for all skin types, and better control of skin surface temperature, thereby lessening the risk of burns.

Autologous Fat Transfer: Similar to dermal fillers, fat transfer provides volume to areas of relative atrophy due to facial aging. It is natural, safe, and long lasting compared to some fillers. Fat is harvested from donor sites such as the flank, abdomen, or gluteal areas. The fat is allowed to sediment, rather than centrifuged, to separate intact fat cells from the ruptured fat cells (top oily layer) and serosanguinous layers. Small aliquots of 0.1-0.2 cc per site are then injected with 1 cc syringes to recreate fullness in the temples, upper and lower lids, glabella, cheeks, nasolabial folds, lips, and jaw line. Similarly, Ellbogen and Rubin describe their technique utilizing fat harvested from the back as stem cell face lifting. In summary, facial rejuvenation is a complex but exciting art dealing with individual layers of the face, yet refining them as a whole facial system. The world of minimally invasive facial rejuvenation is vast and constantly changing. Through continued research and surgical refinement, a more advanced understanding of facial aging will greatly benefit our care of patients.

Acknowledgement: My patients operated and treated at Sankara Nethralaya, Chennai, Apollo Hospitals, Hyderabad and Centre for Sight, Hyderabad. Dr Cat N. Burkat for being an inspiration and guide for this article.

REFERENCES

1. Larrabee WF Jr, Makielski KH, Henderson JL. Surgical anatomy of the face. Lippincott Williams and Wilkins. 2nd Edition.
2. Putterman's Cosmetic and Oculoplastic Surgery (Ed. Steven Fagien). Saunders and Elsevier. 4th edition.
3. Cohen SR, Born TM. Facial rejuvenation with fillers (Ed. Mark A Codner). Saunders and Elsevier. 1st Edition.
4. www.medestheticsmagazine.com. May-June 2009
5. www.aestheticmagazine.com May-June 2009
6. Lucarelli MJ, Lemke BN. Small incision external levator repair: technique and early results. Am J Ophthalmol. 1999; 127:637-44.
7. Dresner SC. Minimal ptosis management. Int Ophthalmol Clin. 1997; 37:151-62.
8. Nahai FR, Nahai F. Minimally invasive facial rejuvenation (Ed. Mark A Codner). Saunders and Elsevier. 1st Edition.
9. Kahana A, Lucarelli MJ. Adjunctive transcanthotomy lateral suborbicularis fat lift and orbitomalar ligament resuspension in lower eyelid ectropion repair. Ophthalm Plast Reconstr Surg. 2009; 25:1-6.
10. Bukvić Mokos Z, Lipoženić J. Corrective dermatology: yesterday- today – tomorrow. Acta Dermatovenerol Croat. 2009; 17:84.
11. www.plasticsurgerypractice.com. May 2009

Correspondence:



Dr Shubhra Goel MD

Consultant, Ophthalmic Plasty and Facial Aesthetics
Apollo Hospitals, Jubilee Hills, Hyderabad
Email – drshubhragoel@gmail.com



Telangana Ophthalmological Society

NOTIFICATION

Election for the post of Vice-President TOS (2015-16)

As per the powers vested in me as the Hon. Gen Secretary APOS, I invite nominations for the post of vice president for the year 2015-16. The nomination should be on a plain paper, proposed & seconded by one ratified member each & should be accepted by the candidate. The date of the candidate joining the society as member / Life member & years in which he/she was a member of the MC in the erstwhile APOS should be clearly mentioned in the proposal to decide eligibility.

Eligibility:

The candidate shall be a life member of at least 8 years in good standing and should have been an office bearer / member of MC in the erstwhile APOS in the past for at least one term.

Schedule of Election:

Last date for receipt of Nominations – **30th April 2015 – 5 PM**

Date of Scrutiny – **2nd May 2015**

Last Date of Withdrawal – **22nd May 2015 – 5 PM**

Election if required shall be during the General Body meeting on 20th June 2015 at Karimnagar.

The nominations may be sent in a sealed cover to me at
Teja Eye Hospital, Kakaji Colony, Hanamakonda, Warangal district, Telangana

Date 20th March 2015

Dr A Ravindra
Hon. Gen. Secretary, TOS

To maintain your edge,
your equipment has to keep up.



Invest in the only laser system that allows for integration with the CONSTELLATION® Vision System.

Only the PUREPOINT® Laser is designed to enhance your procedures today and tomorrow. As a stand-alone laser or as part of the CONSTELLATION® Vision System, the PUREPOINT® Laser delivers the performance you expect from the world leader in retinal surgery:

- **Advanced.** Features cutting-edge laser technology, including voice confirmation.
- **Versatile.** Provides enhanced ease of use and efficiency.
- **Robust.** Compatible with a full line of laser probes and accessories.
- **Adaptable.** Enables future integration when upgrading to the CONSTELLATION® Vision System.

To learn more about the PUREPOINT® Laser, contact your local Alcon sales representative.

Alcon®

PUREPOINT
L A S E R 

Welcome to the new possible.

1st ANNUAL CONFERENCE



Telangana Ophthalmological Society

20th & 21st June, 2015 ; Venue: Prathima Institute of Medical Sciences, Nagunur, Karimnagar
Organised by: Karimnagar Ophthalmological Association

CONFERENCE HIGHLIGHTS

1. Video Sessions
2. Wet Labs
3. Interesting programmes for PGs, Quiz
4. Trade Exhibition with excellent participation
5. Cultural activities related to the region
6. Sight seeing tours and entertainment

Organising Committee

CHIEF PATRONS

Dr B Srinivas Rao

Chairman & MD PIMS

Dr C Laxmi Narsimha Rao

Chairman CAIMS

PATRONS

Dr A Vivekananda M.S.(OBG), Dean PIMS

Dr Ravinder Rao M.S. Medical Superintendent PIMS

Dr V Suryanarayana Reddy M.S., Managing Director, CAIMS

ADVISORS

Dr B Venkat Reddy
Dr G Hari Kishan
Dr M Sanjay Kumar
Dr J V N Reddy
Dr A Devender Reddy
Dr V Devender Reddy
Dr G Laxmana Murthy
Dr Ch Kanthaiiah
Dr K Venkat Raja Reddy
Dr P Sridhar

Dr B Krishnamurthy
Dr K Suresh Chander Rao
Dr. K Sampath Kumar
Dr. B Chokkaiah
Dr Ch Srinivas Reddy
Dr Ch Narsaiah
Dr Ch Venkateshwarlu
Dr D Niranjana
Dr B Muralikrishna

CHAIRMAN

Dr. G . Badrinarayana, M.S.

ORGANISING SECRETARY

Dr. Ch. Jaganmohan Rao, D.O.

TREASURER

Dr V Raghu M.S.

JOINT ORGANISING SECRETARIES

Dr Srikrishna Ingle M.S.

Dr S Ramakrishna D.O.

Dr B Anil Kumar M.S.

CO-ORDINATORS

Dr Viiay Deshmukh
Dr G Rambabu
Dr M Umashankar
Dr M Srinivas
Dr Ch Srilatha
Dr Ch Sindhu Sulekha
Dr R Aravind
Dr G Harika
Dr A. Vani
Dr B Shruthi

Dr G Harika
Dr M Mrudula Reddy
Dr A Eshikasri
Dr P Shwetha
Dr Md Mudasiruddin
Dr B Vijay
Dr S Venkateshwarlu
Dr K Ratnamala
Dr D Sudheer Reddy



CHAIRMAN

Dr G Badrinarayana M.S.



Organising Secretary

Dr Ch Jaganmohan Rao MBBS, DO
Incharge Ophthalmology Dept. PIMS



TREASURER

Dr V Raghu M.S.



Scientific Abstract Submission

For Instruction Course / Paper / Video / Poster / Case Presentation

First Annual Conference of the

Telangana Ophthalmological Society

June 20 - 21, Karimnagar (Organized by the Karimnagar Ophthalmological Association)

SUBMISSION CATEGORY (Please tick)

Competitive Sessions

(Eligibility criteria: all ratified life members of erstwhile APOS who are resident in the state of Telangana)

- P Ramchander's Free paper session
- Shoba Harikishen's free paper session (Private practitioners only)
- Manoj Mathurs' poster session
- N Subramanya Reddy's free paper session (Residents only)
- Swarup's video session
- Non Competitive paper session**

Instruction Course:

Skills transfer course:

AUTHOR / INSTRUCTOR INFORMATION

Chief Author/ Chief Instructor:
 APOS/TOS Membership Number:
 Address:

Phone / Mobile:
 E-mail address:

Co-Authors / Co-Instructors

1. Name
Membership Number
2. Name
Membership Number
3. Name
Membership Number

Abstract

(To be typed in single space within the box in 300 words / 25 lines max in the given format.)

1. Format for FP/Poster: Title/ Purpose / Methods / Results / Conclusions
2. Format for Video: Title/ Synopsis
3. Format for Instruction Course: Title/ Objective / Course Content / Conclusions

Important dates

Last date for abstract submission: April 15
 Confirmation of acceptance: April 30

Please send filled in copies of this form by surface mail or by email to:

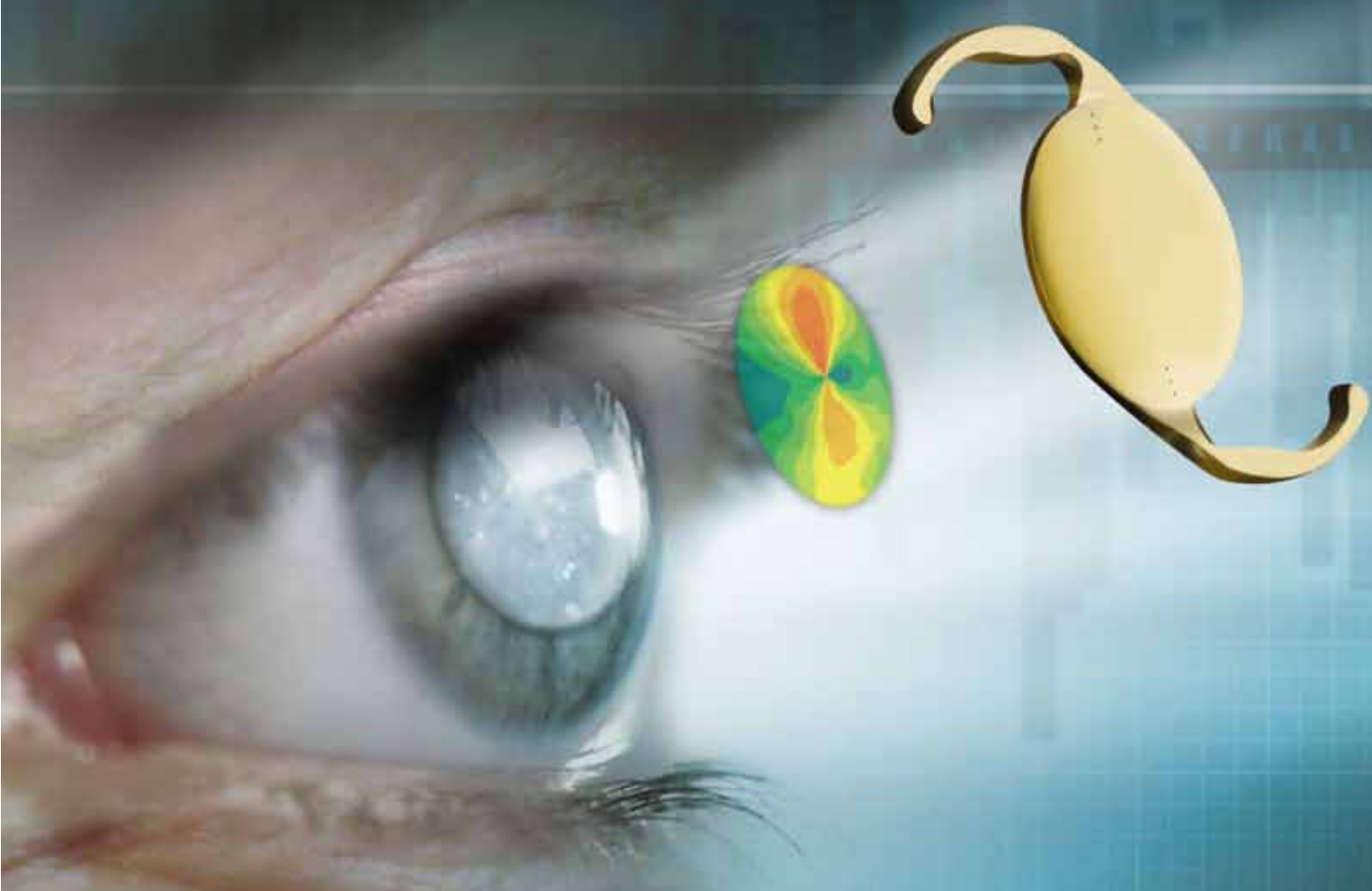Dr Pravin K Vaddavalli

Chairman, Scientific Committee, TOS
 Cornea Service
 LV Prasad Eye Institute
 Road No 2, Banjara Hills
 Hyderabad - 500034
 Email: pravin@lvpei.org
 Mobile: 9849094245

Scientific committee Members

Dr Ashok Madiraju
 Dr Rishi Swarup
 Dr Samatha G
 Dr Srinivas Prasad K

CATARACT
ASTIGMATISM



Recognize both.
Recommend AcrySof® IQ Toric IOL.

CONFIDENCE

THE ACRY Sof
ADVANTAGE

Recommend the AcrySof® IQ Toric IOL
for your astigmatic cataract patients.

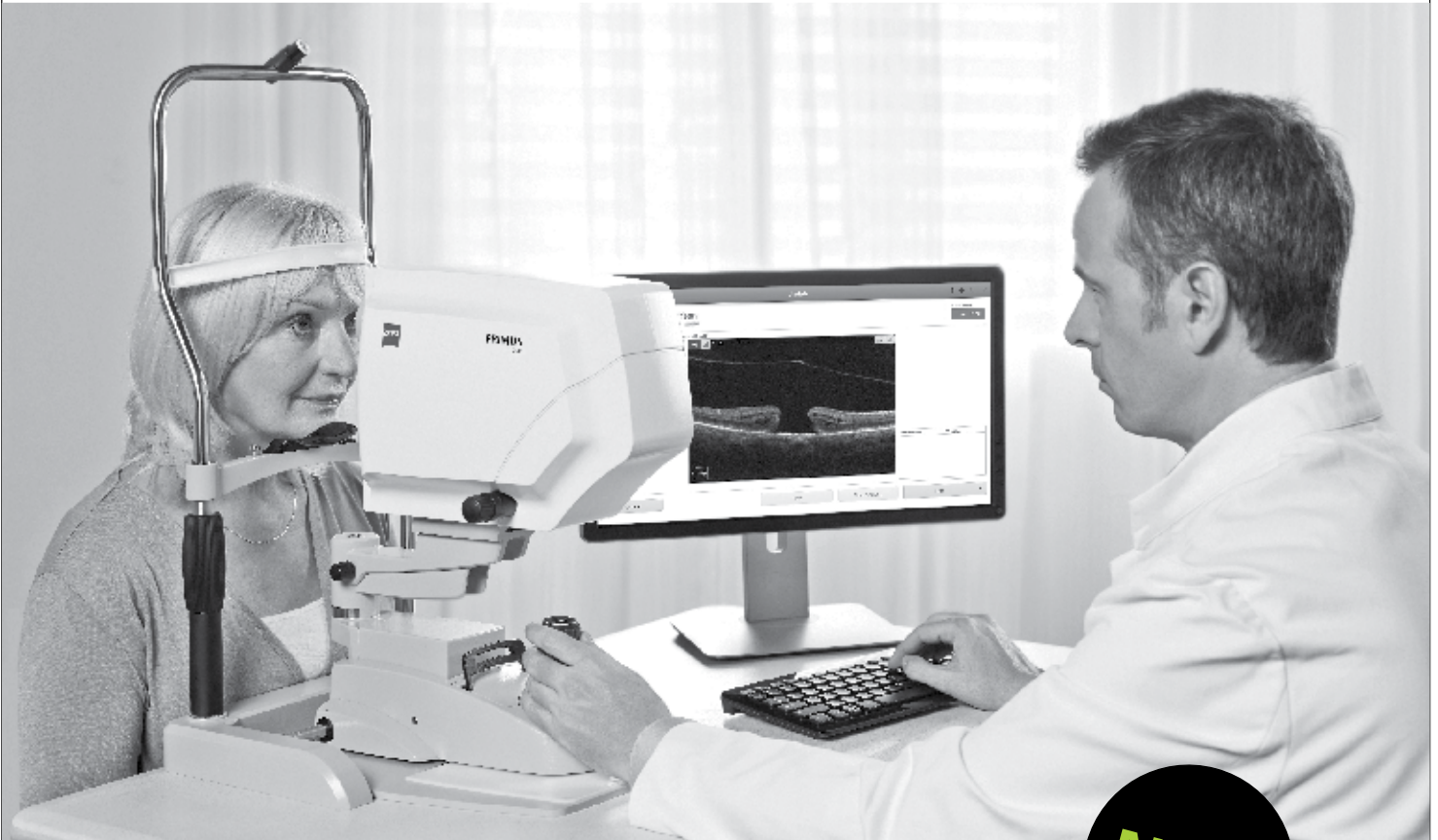©2010 Alcon, Inc. 12/10 TOR10286JAD For International (non-USA) Use Only.

Alcon®

ACRY Sof IQ
TORIC
ASTIGMATISM IOL



The moment you look beyond the surface with ease.
This is the moment we work for.



PRIMUS 200

Simplicity in your hands. Growth in your practice.

Your first essential OCT

- Easy to Approach
- Easy to Use
- Easy to Interpret

Talk to your ZEISS Representative today.

Carl Zeiss India(Bangalore) Pvt. Ltd

Toll Free No: 1800 103 0403 | + 91 80 4940 5757
medindia@zeiss.com | www.zeiss.co.in

NEW



We make it visible.

TOC 2015



1st Annual Conference of Telangana Ophthalmological Society
on 20th & 21st June 2015, Venue: Prathima Medical College, Karimnagar.

Registration Form

Before filling the form 1. Fill in Block Letters 2. Xerox this form to be used by your accompanying person / spouse / child

Category : TOS / APOS Member Non Member Resident / Guest / Trade Deligate

Name : _____

Address: _____

Land Phone : _____

Email : _____ Mobile No. _____

Food Reference : Veg Non Veg Non Eating

Registration Category :	Tick as applicable	Before May 20th / After May 20th
TOS/APOS Membership	<input type="checkbox"/>	Rs. 2000-00 / 2500-00
Non Member	<input type="checkbox"/>	Rs. 2500-00 / 3000-00
Resident/Guest/Trade Deligate	<input type="checkbox"/>	Rs. 1500-00 / 2000-00

Payment Details : Find enclosed herewith the DD in favour of "TOC-2015" for Rs. _____
(Rupees in words _____ only) Payable at Karimnagar
DD No. _____ Dated : _____

Please send the registration form along with DD to Conference Secretariate, Dr. Ch.Jaganmohan Rao, MBBS, DO
(Incharge Ophthalmology Dept. PIMS), Organising Secretary, Mamatha Vani Eye Hospital, # 2-8-115, Beside
Circus Ground, Mukarampura, Karimnagar. e-mail : jmraochennadi@gmail.com, Cell: 9866311145

For office Use :

Payment Deposited on
Acknowledgement sent on
Data uploaded on

Payment Realised on
Receipt No.
Registration No.

TOC 2015 KARIMNAGAR HOTELS INFORMATION

Name of the Hotel	Phone Number	E Mail ID	TARIFF		
Prathima Regency	0878-2233666 Fax: 0878-2233466	sales.prathimaregency@gmail.com	Room Type	Single	Double
			Standard	1800	2100
			Deluxe	2100	2400
			Executive Suite	3500	
Hotel Swetha	0878-2244333 (4 Lines) Fax: 0878-2251333	hotelswethaknr@gmail.com	Deluxe	2200	2600
			Executive Deluxe	2600	3000
			Swetha Suite	3500	4000
Hotel Maitri	0878-2241666, 2243666	maitriresidencyknr@gmail.com	Premium	1600	2200
			Executive Suite	3500	
Hotel Manair	0878-2240425, 2264517	hotelmanair@gmail.com	A/c Super Deluxe	1399	
			A/c Deluxe	999	
Hotel Srinivasa	0878-2243201, 2243202	hotelsrinivasa@yahoo.com	A/c Deluxe	1470	
			A/c	1260	
Hotel Nawab's	0878-2231777	visit@hotelnawabs.com	Deluxe	999	
			Executive	1199	

1st ANNUAL CONFERENCE



Telangana Ophthalmological Society

20th & 21st June, 2015 ; Venue: Prathima Institute of Medical Sciences, Nagunur, Karimnagar

Organised by: Karimnagar Ophthalmological Association

CONFERENCE HIGHLIGHTS

1. Video Sessions
2. Wet Labs
3. Interesting programmes for PGs, Quiz
4. Trade Exhibition with excellent participation
5. Cultural activities related to the region
6. Sight seeing tours and entertainment

Mail the duly filled in Registration Form along with your cheque/DD to:


The Organizing Secretary
Dr. Ch. Jaganmohan Rao, DO
Incharge Ophthalmology Dept. PIMS
Mamatha Vani Eye Hospital
2-8-115, Beside Circus Ground, Mukarampura
Karimnagar.



**APPLICATION FOR LIFE MEMBERSHIP OF
TELANGANA OPHTHALMOLOGICAL SOCIETY
HYDERABAD.**

Applied For Life Member _____ Member in waiting _____

(Existing APOS members need not apply)



Name (In Block Letters)

Father's / Husband's Name:

Age: Sex: Date of Birth:

Native District

Address (Present)

.....

.....

.....

Address (Permanent)

.....

.....

.....

Mobile: E-mail:

Designation :

Academic Qualification:

MBBSYear: PG DO. MS DNB Year..... (For Life Member)

Joined PG in Ophthalmology Year: (for member in - waiting)

Note : Existing APOS members need not apply.

Date :

Signature of the candidate

Membership Fee: Rs. 2,000 for Practitioners
Rs. 1,500 for PGS

DD/At Par Cheque No. :

Remarks of Secretary :

DD/Cheque in favour of "TELANGANA OPHTHALMOLOGICAL SOCIETY" Payable at Hyderabad.

Kindly send the completed forms to: Dr. A. RAVINDRA, Teja Eye Hospital, H.No. 6-2-58,

Kakaji Colony, Hanamkonda- 506001 . Cell: No. 98664 26367

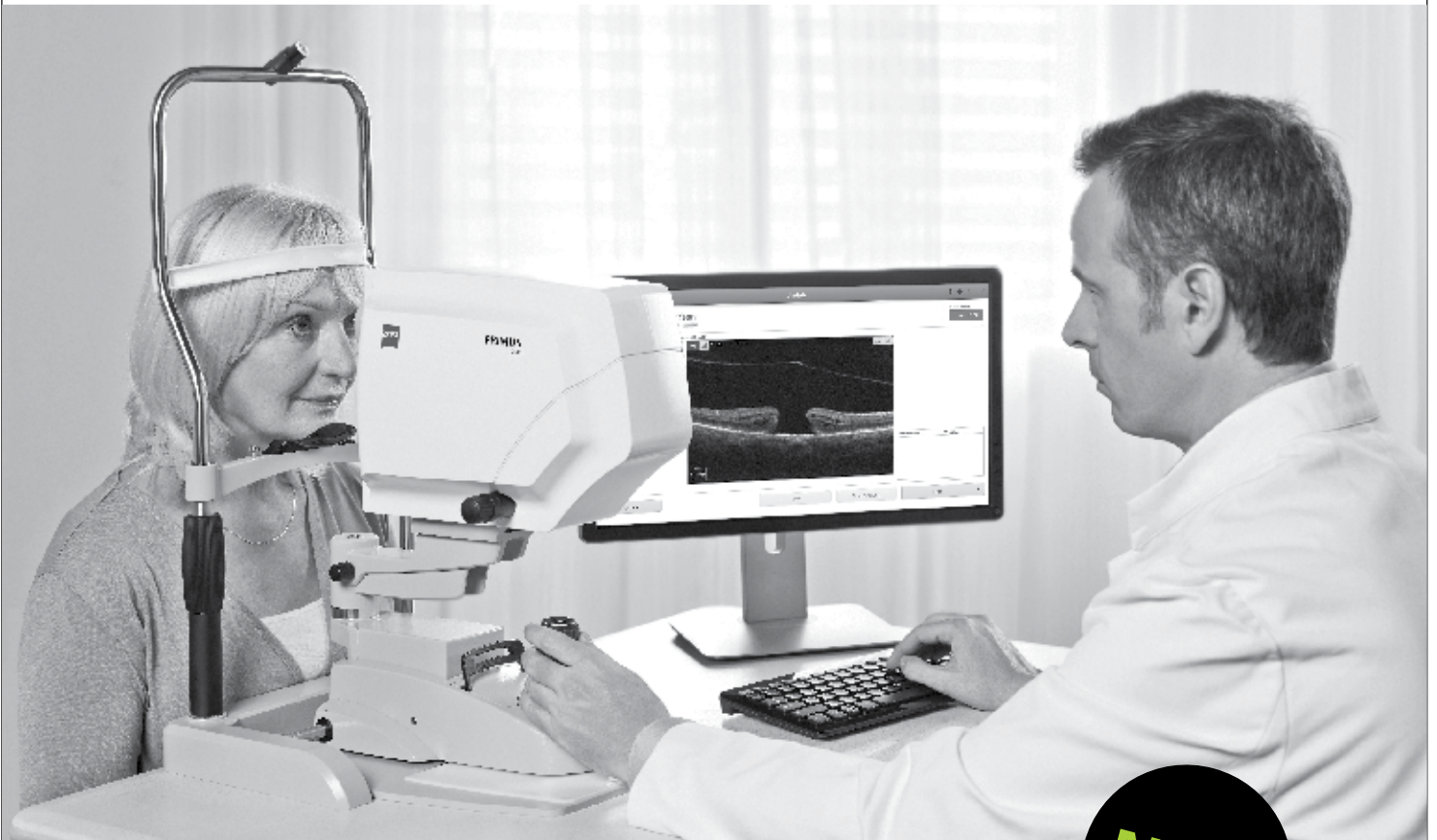

TELANGANA OPHTHALMOLOGICAL SOCIETY
HYDERABAD.

Mail the duly filled in Registration Form along with your cheque/DD to:

Dr. A. RAVINDRA,
Teja Eye Hospital,
H.No. 6-2-58,
Kakaji Colony, Hanamkonda- 506001
Cell: No. 98664 26367

The moment you look beyond the surface with ease.
This is the moment we work for.



NEW

PRIMUS 200

Simplicity in your hands. Growth in your practice.

Your first essential OCT

- Easy to Approach
- Easy to Use
- Easy to Interpret

Talk to your ZEISS Representative today.

Carl Zeiss India(Bangalore) Pvt. Ltd

Toll Free No: 1800 103 0403 | + 91 80 4940 5757
medindia@zeiss.com | www.zeiss.co.in



We make it visible.

SONY

Recognised
for quality



Sony Camera and Video Recorders/ Surgery Recorders

PMW-10MD: Sony 3 Chip Full Medical Camera
(Inbuilt HD Recorder)

MCC-500MD: Sony Single chip Full HD Camera

MCC-3000MT: SONY 3D Medical Camera

DXC-C33P: Sony 3 Chip SD Camera

HVO-550MD: Sony FULL HD Recorder/USB/DVD

HVO- 3000MT: Sony 3D Video Recorder

LMD-2110MD : Sony 21" HD Medical Monitor

LMD-2765: Sony 27" HD Medical Monitor

LMD- 3251MT: Sony 32" 3D Monitor



Head office:
RZ-37/6, IIIrd Floor, Tughlakabad Extension
New Delhi 100019, India
Mr. Dinesh Mahajan : +91 99100 68423
Mr. Tarun Puri : +91 9811 900958
Email: sales@dahealthcare.com
Phone Number: +91.11.29993840
Fax Number: +91.11.29993855

Branch Office:
new no.2 old no.14
Budda Street
Rangarajapuram, Kodambakkam
Chennai-24
Contact: E.Saravanan
Email : saravanan@dahealthcare.com
Mobile: +91 90030 72177

www.dahealthcare.com